



Incidentiloma


Dr Naeem Zia

FCPS,FACS,FRCS




Learning objectives

- To define incidentiloma
- Appreciate the importance of incidentiloma
- Enumerate the investigations for incidentiloma
- Management of incidentiloma

- 
- an **incidentaloma** is a Tumor (-oma) found by coincidence (incidentally) without clinical symptoms or suspicion.
 - it is found during the course of examination and imaging for other reasons
 - a common problem: up to 7% of all patients over 60 may harbor a benign growth, often of the adrenal gland,
 - increase of "whole-body CT scanning" as part of health screening programs



- 
- the chance of finding incidentalomas is expected to increase. 37% of patients receiving whole-body CT scan may have abnormal findings that need further evaluation. As many incidentally found lesions may never cause disease, there is a risk of over diagnosis



Adrenal incidentaloma

- Incidental adrenal masses on imaging are common (0.6 to 1.3% of all abdominal CT)
- Differential diagnosis include adenoma, myelolipoma, cyst, lipoma, pheochromocytoma, adrenal cancer, metastatic cancer, hyperplasia, and tuberculosis

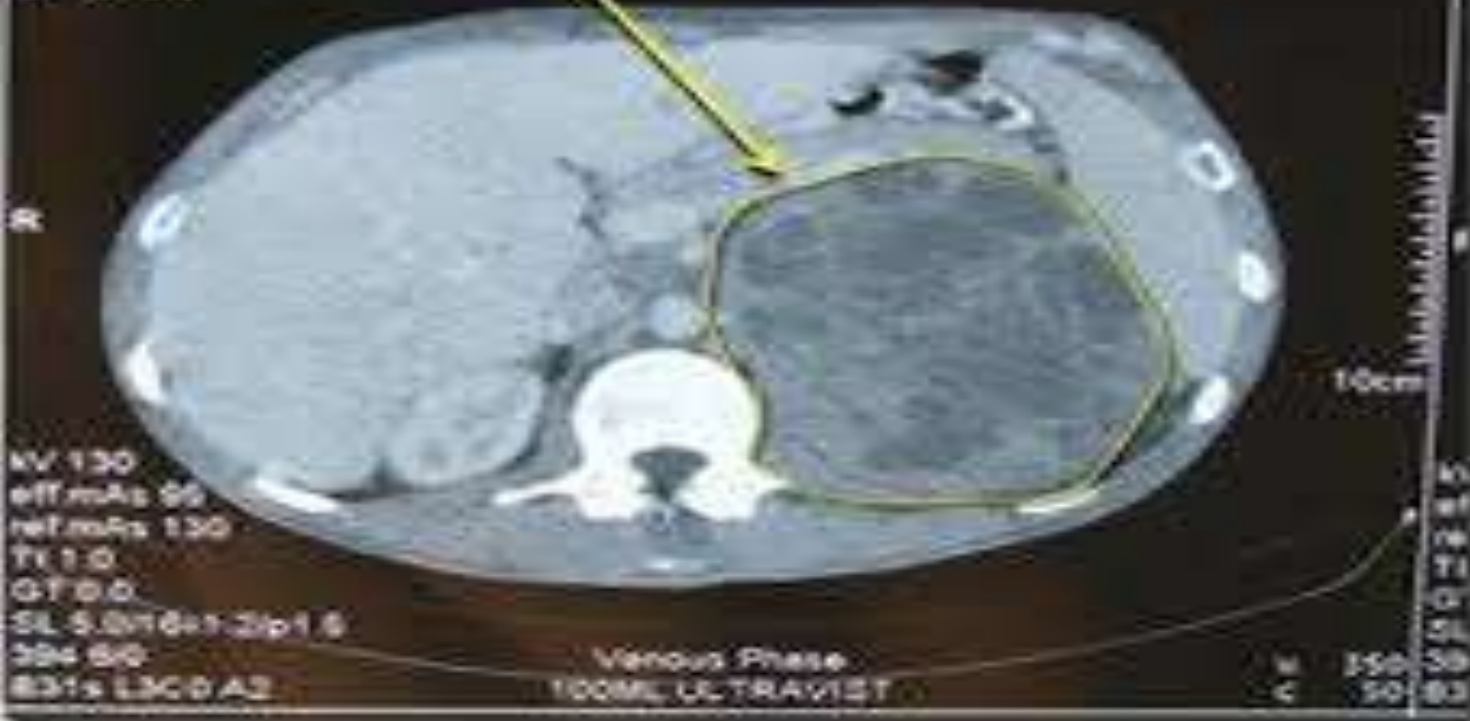WOODMAN MARK, 105544813 A

E945 FOF HB
23/01/1975, M, 35Y

Grange Schuur Hospital
Emotion 16 (2007)
CT 2007E
H-SP-CR

03/02/2010
09:48:07.27
3 IMA 20
SP: 3
SP: -910.6

Adrenal gland tumour
Approx 14.5 x 12.5 cm




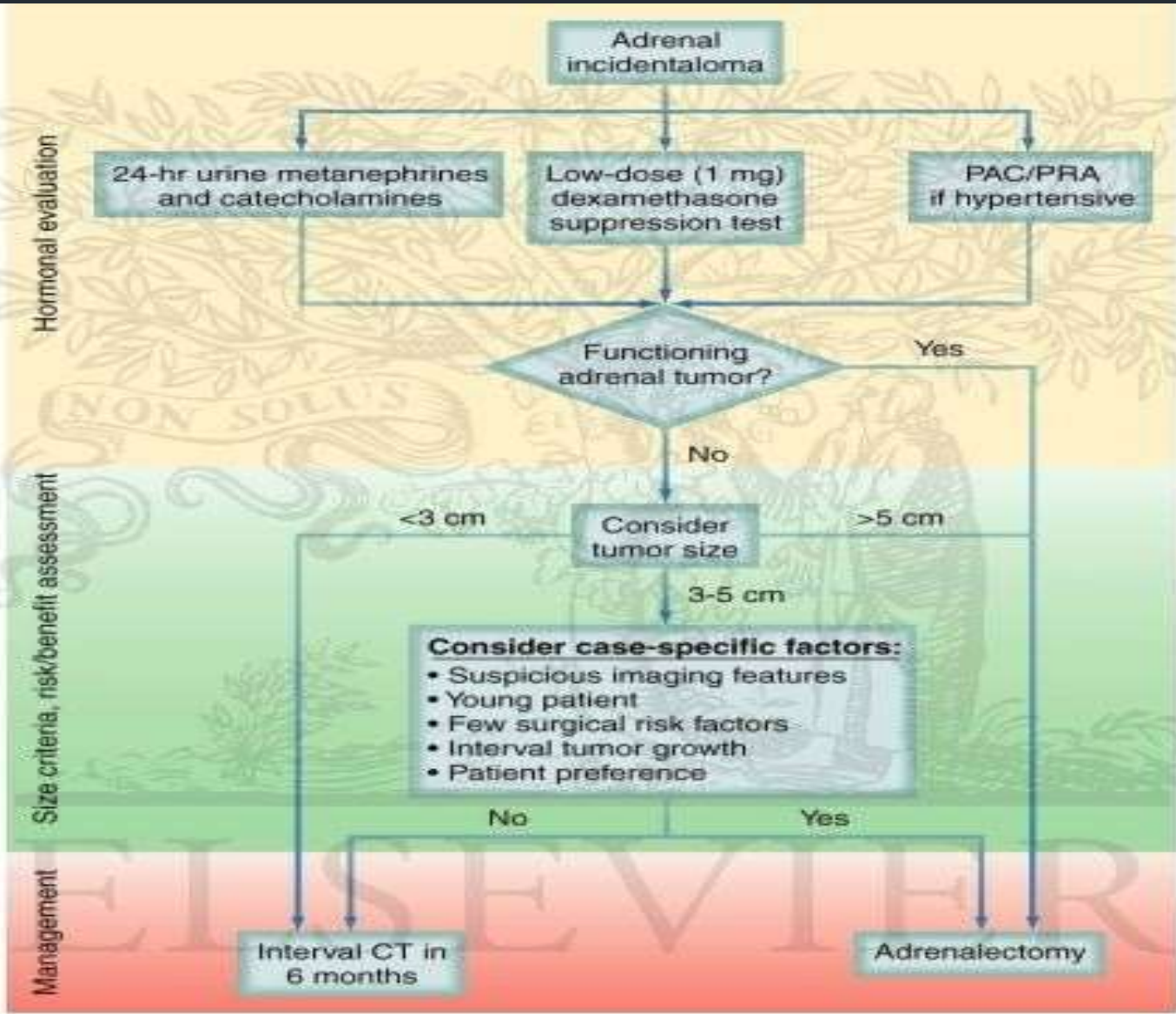
KV 130
eff.mAs 99
ref.mAs 130
TE 1.0
GT 0.0
SL 5.0/16x1.2/p1.6
394 50
831s L3C0 A2

Venous Phase
100ML UL TRAVIST

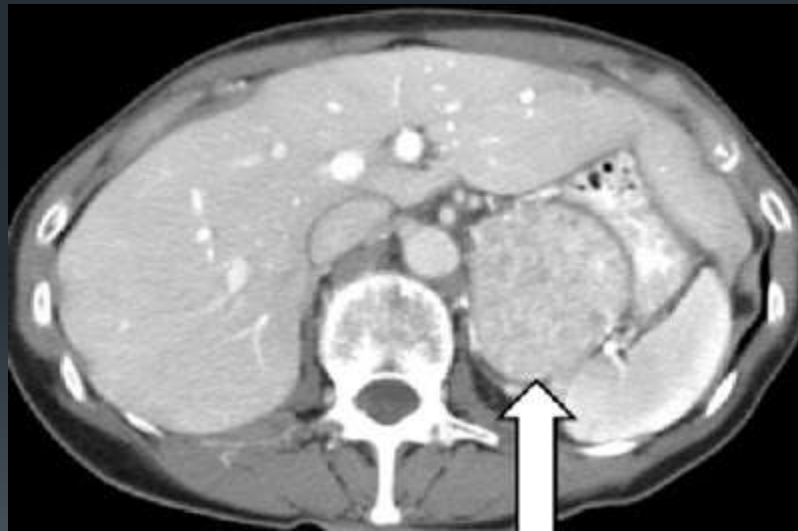
KV 130
C 50

10cm
KV 130
TE 1.0
SL 5.0/16x1.2/p1.6
394 50
831s L3C0 A2

- 
- Management of adrenal incidentiloma
 - More than 4cm
 - Less than 4cm



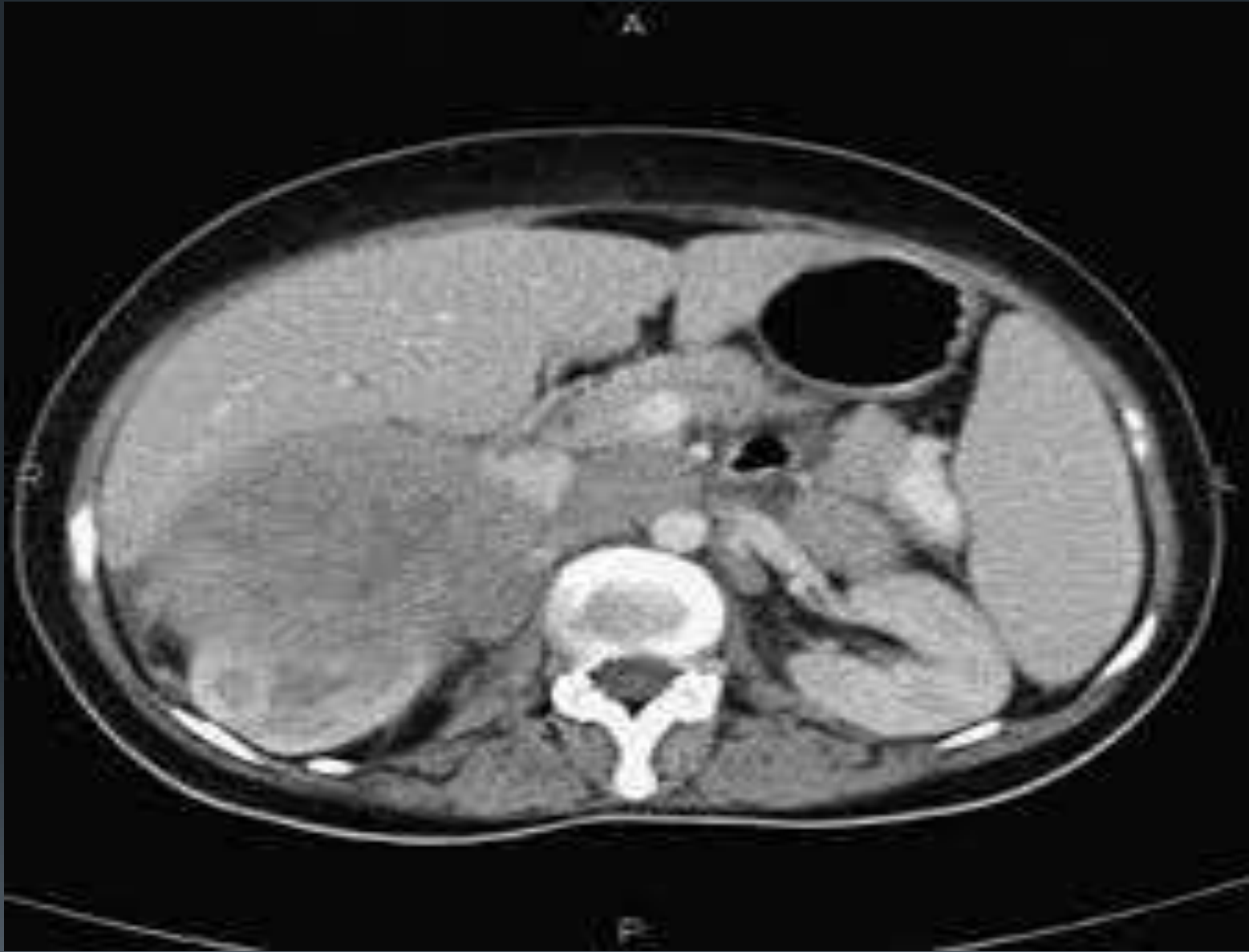Radiographic appearance





Renal incidentaloma

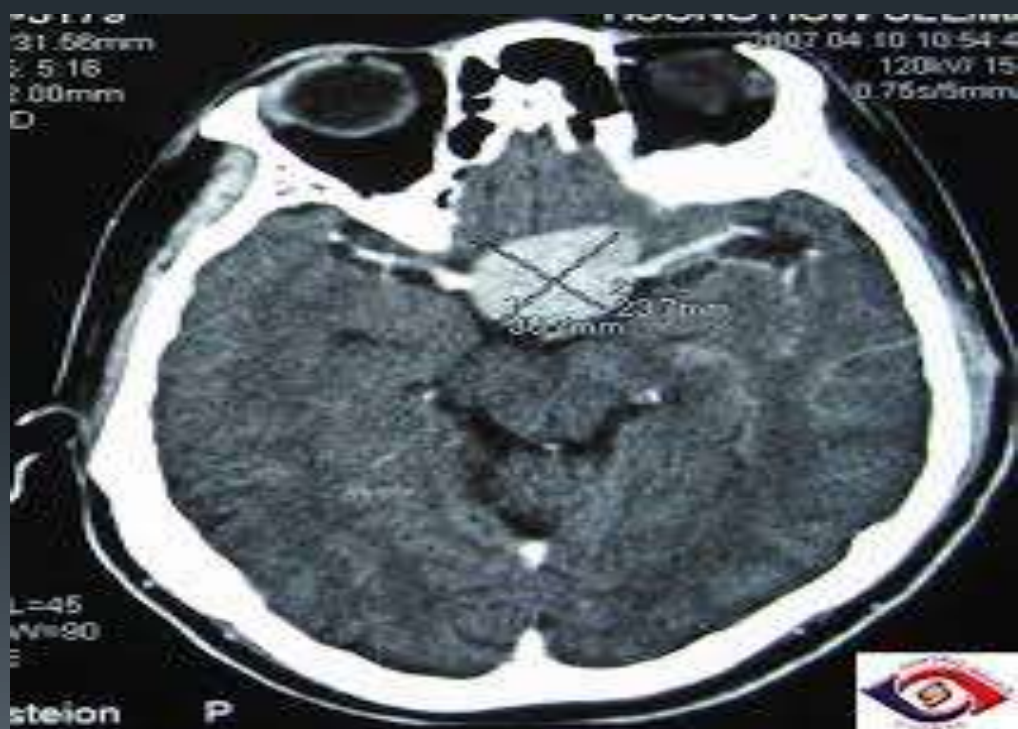- Most renal cell carcinomas are now found incidentally. Tumors less than 3 cm in diameter less frequently have aggressive histology.

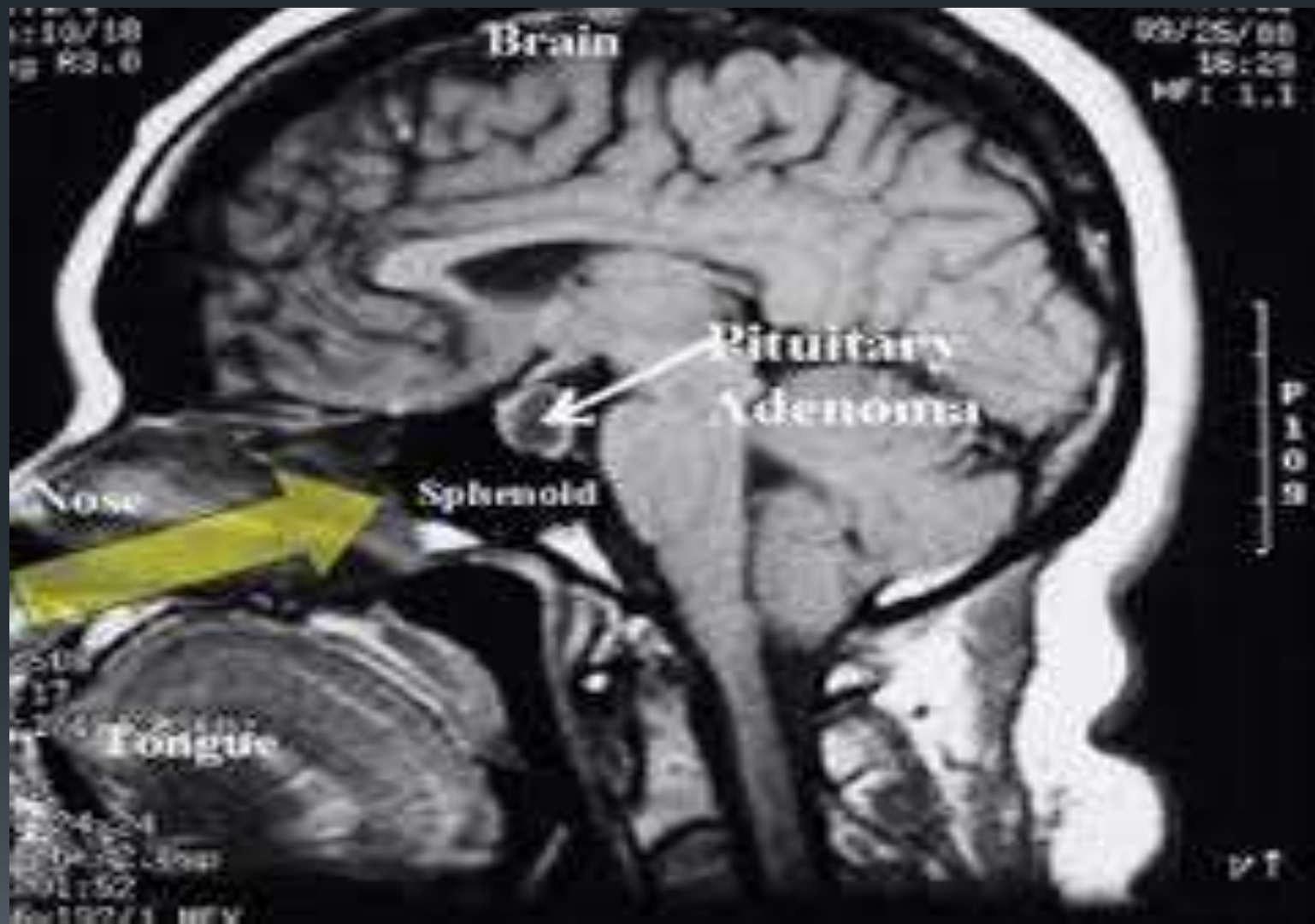




Pituitary incidentaloma

- Autopsy series have suggested that pituitary incidentalomas may be quite common. It has been estimated that perhaps 10% of the adult population may harbor such endocrinologically inert lesions. When encountering such a lesion, long term surveillance has been recommended. Also, a baseline pituitary hormonal function test should be done, including measurements of serum levels of TSH, prolactin, IGF-1 (as a test of growth hormone activity), adrenal function (i.e. 24 hour urine cortisol, dexamethasone suppression test), testosterone in men, and estradiol in amenorrheic women.

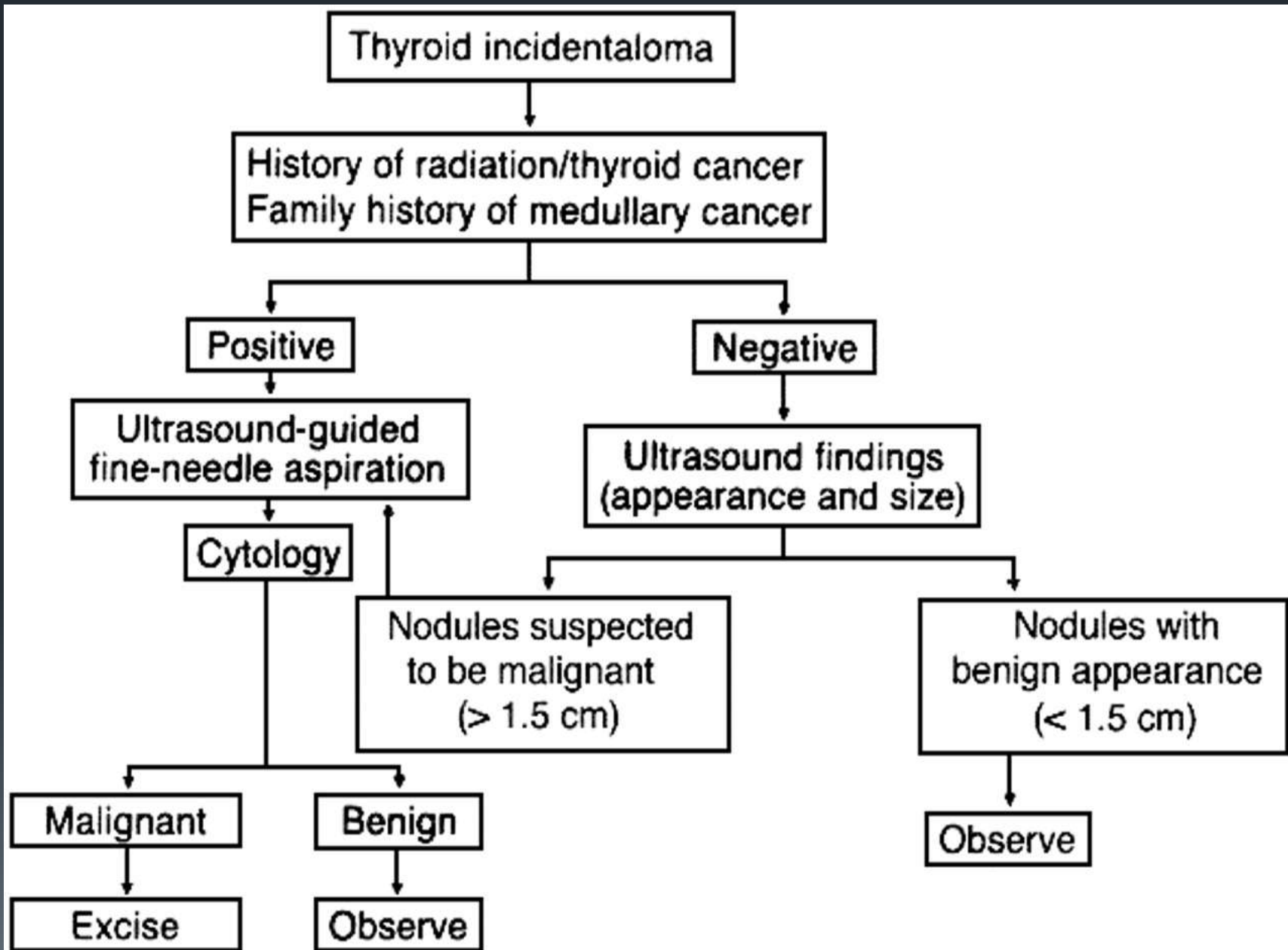






Thyroid incidentaloma

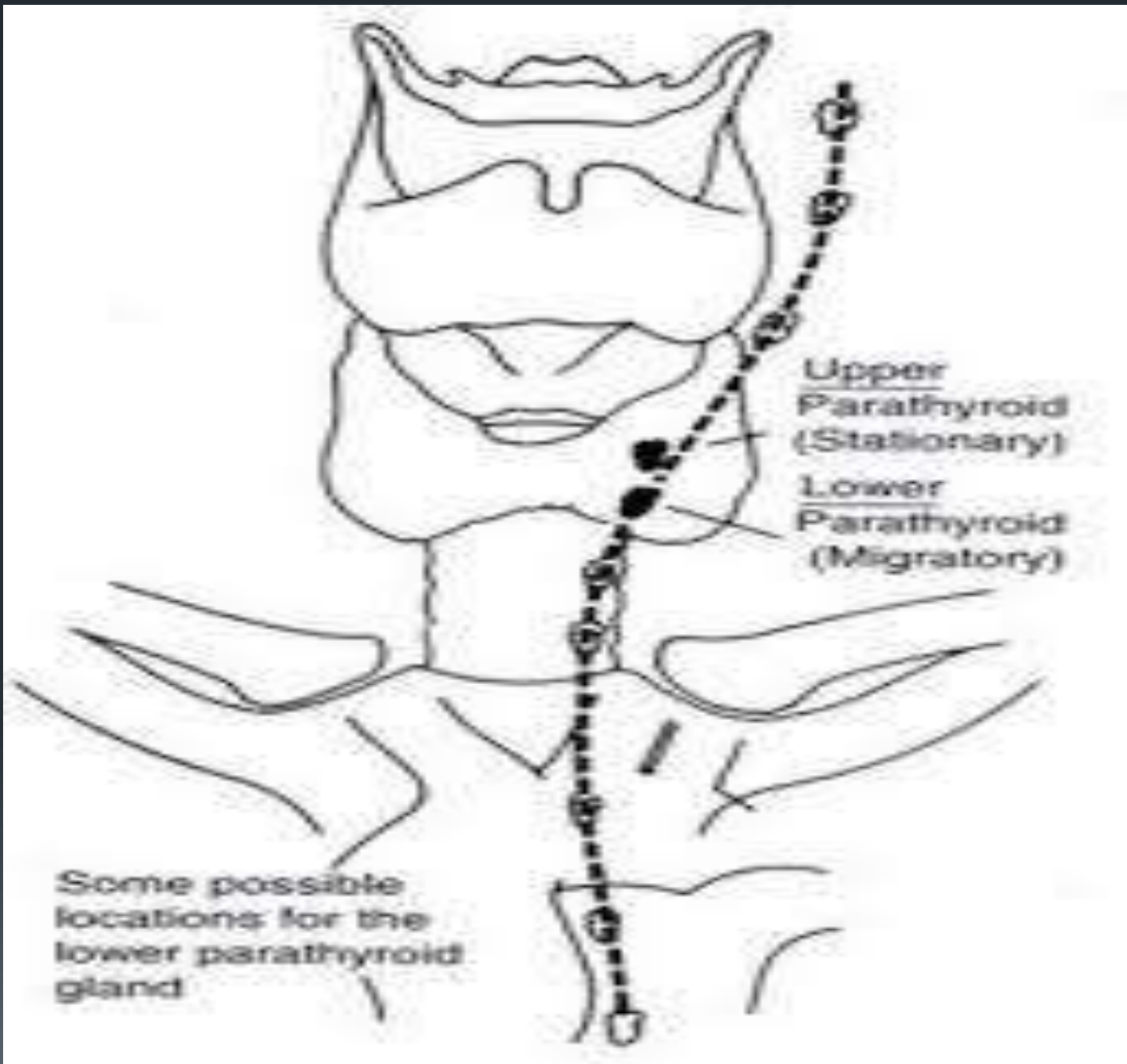
- Incidental thyroid masses may be found in 9% of patients undergoing bilateral carotid duplex ultrasonography.¹
- Some experts recommend that nodules > 1 cm (unless the TSH is suppressed) or those with ultrasonographic features of malignancy should be biopsied by fine needle aspiration. Computed tomography is inferior to ultrasound for evaluating thyroid nodules. Ultrasonographic markers of malignancy are:
 - solid hypoechoic appearance
 - irregular or blurred margins
 - intranodular vascular spots or pattern
 - microcalcifications





Parathyroid incidentaloma

- Incidental parathyroid masses may be found in 0.1% of patients undergoing bilateral carotid duplex ultrasonography.





Pulmonary nodule

- Studies of whole body screening computed tomography find abnormalities in the lungs of 14% of patients. Clinical practice guidelines by the American College of Chest Physicians advise on the evaluation of the solitary pulmonary nodule



Lumbosacral spine

- The increasing use of MRI, often during diagnostic work-up for back or lower extremity pain, has led to a significant increase in the number of incidental findings that are most often clinically inconsequential. The most common include:
 - vertebral hemangioma
 - fibrolipoma
 - Tarlov cyst