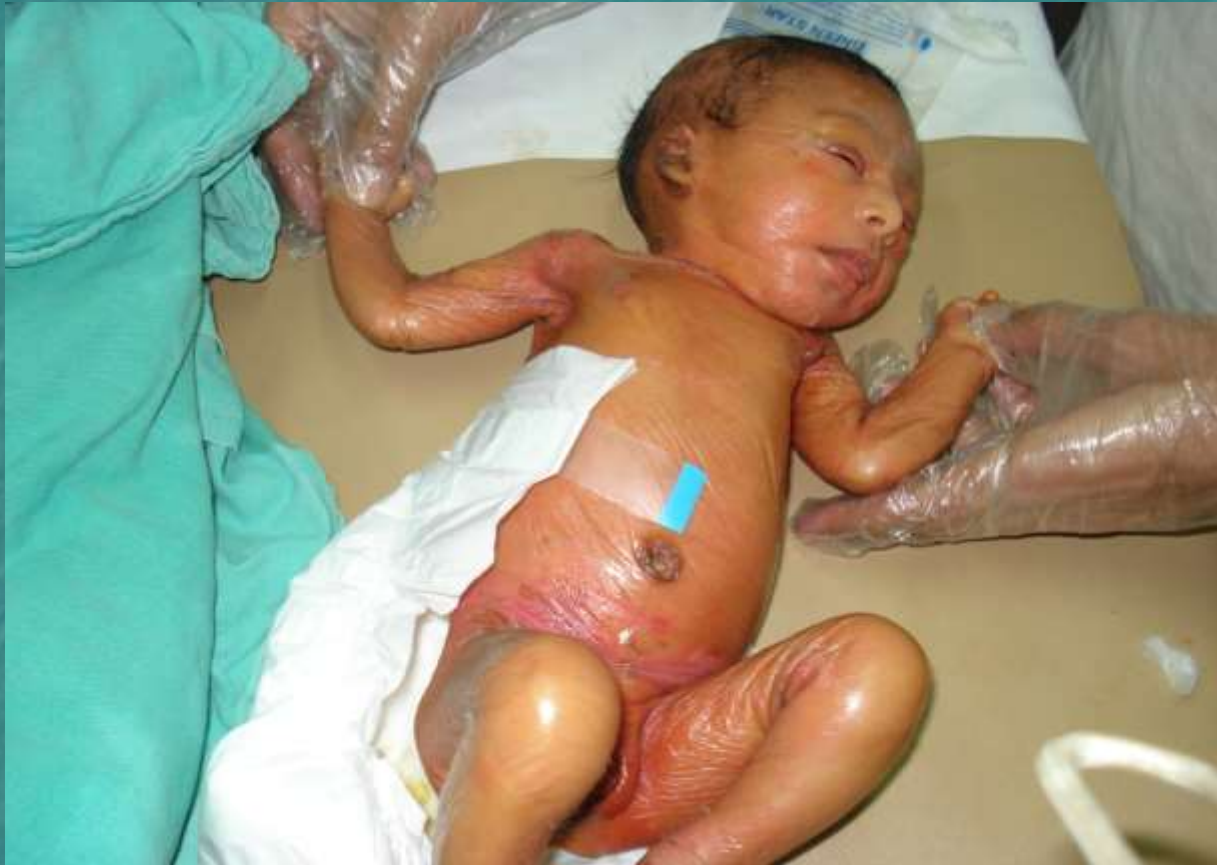

# **COLLODION BABY**

**Dr Uzma Ali**  
**Dermatology Department**  
**Capital Hospital**  
**Islamabad**

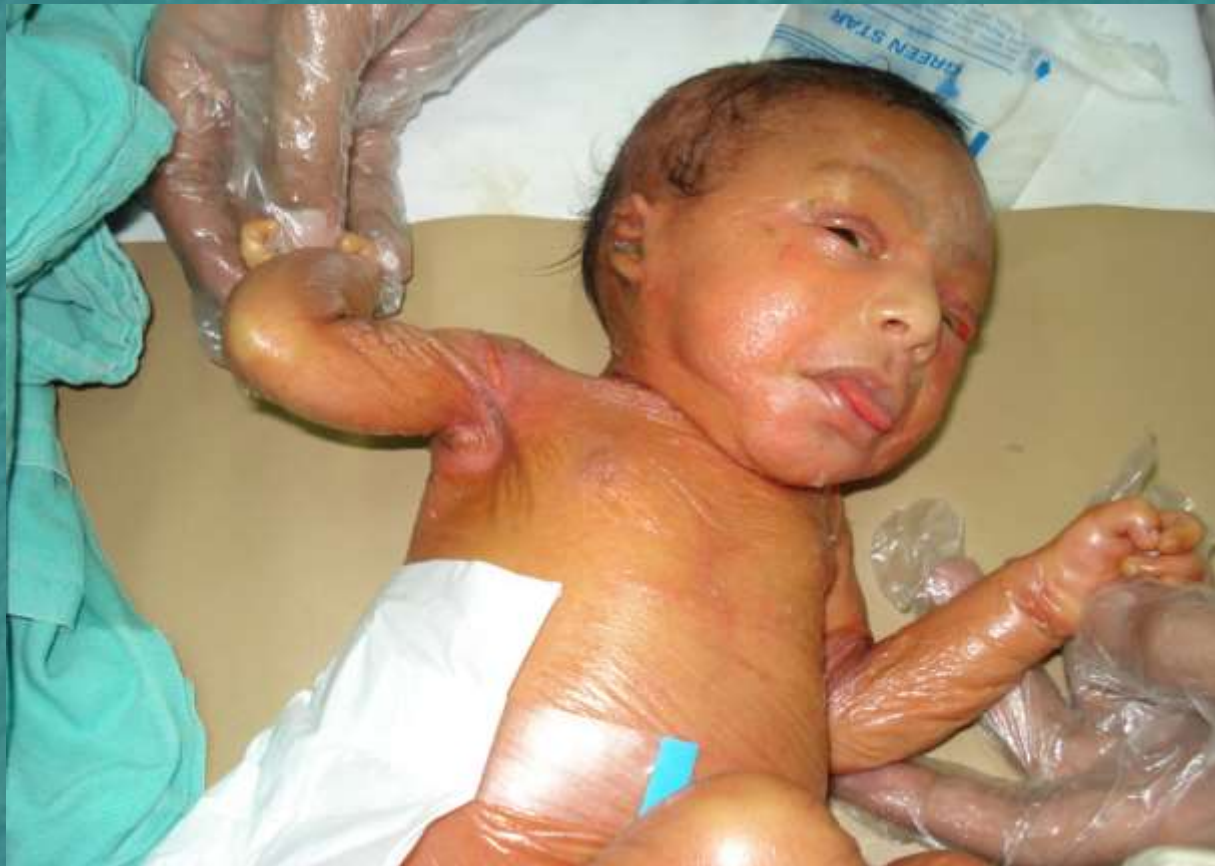# Collodion baby



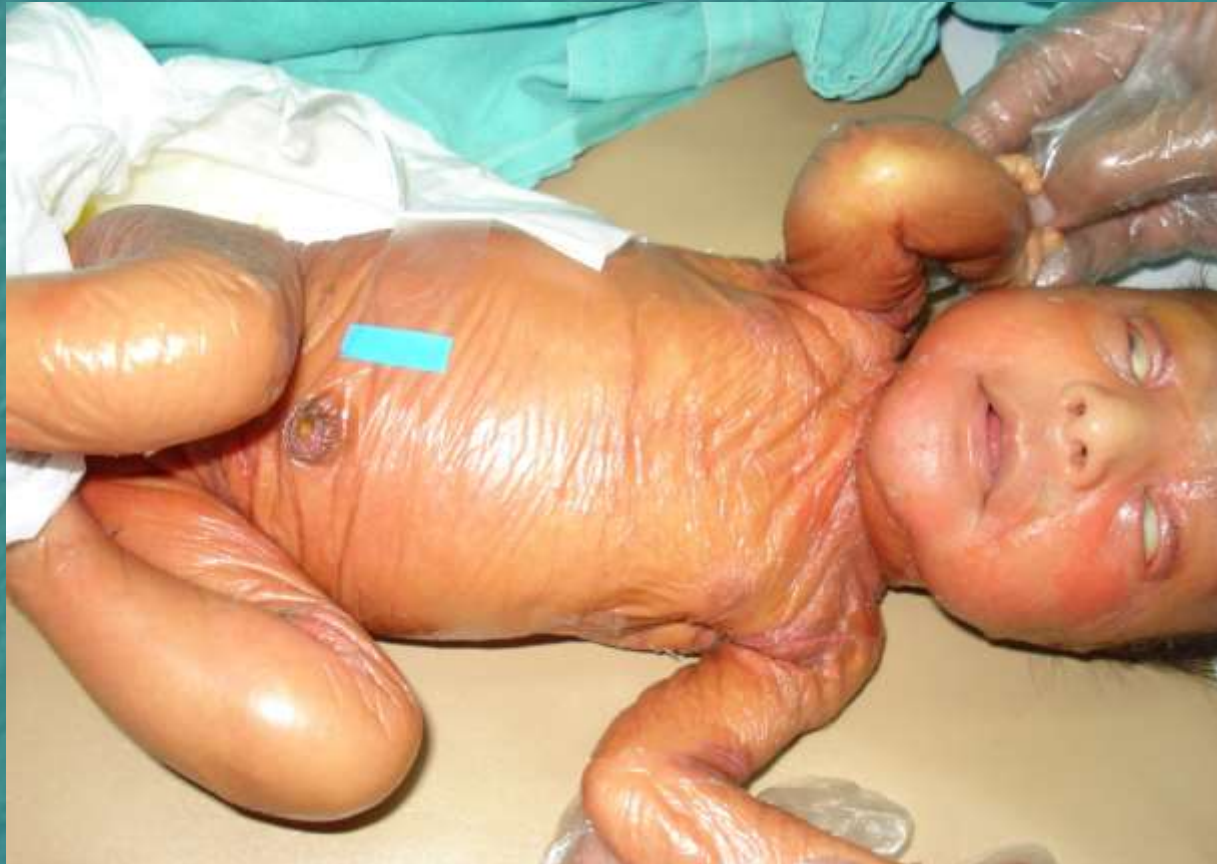# History

- 4 wks old baby
- Born to parents of cousin marriage
- H/O similar problem in two older siblings
- Was born in same state

# Collodion baby



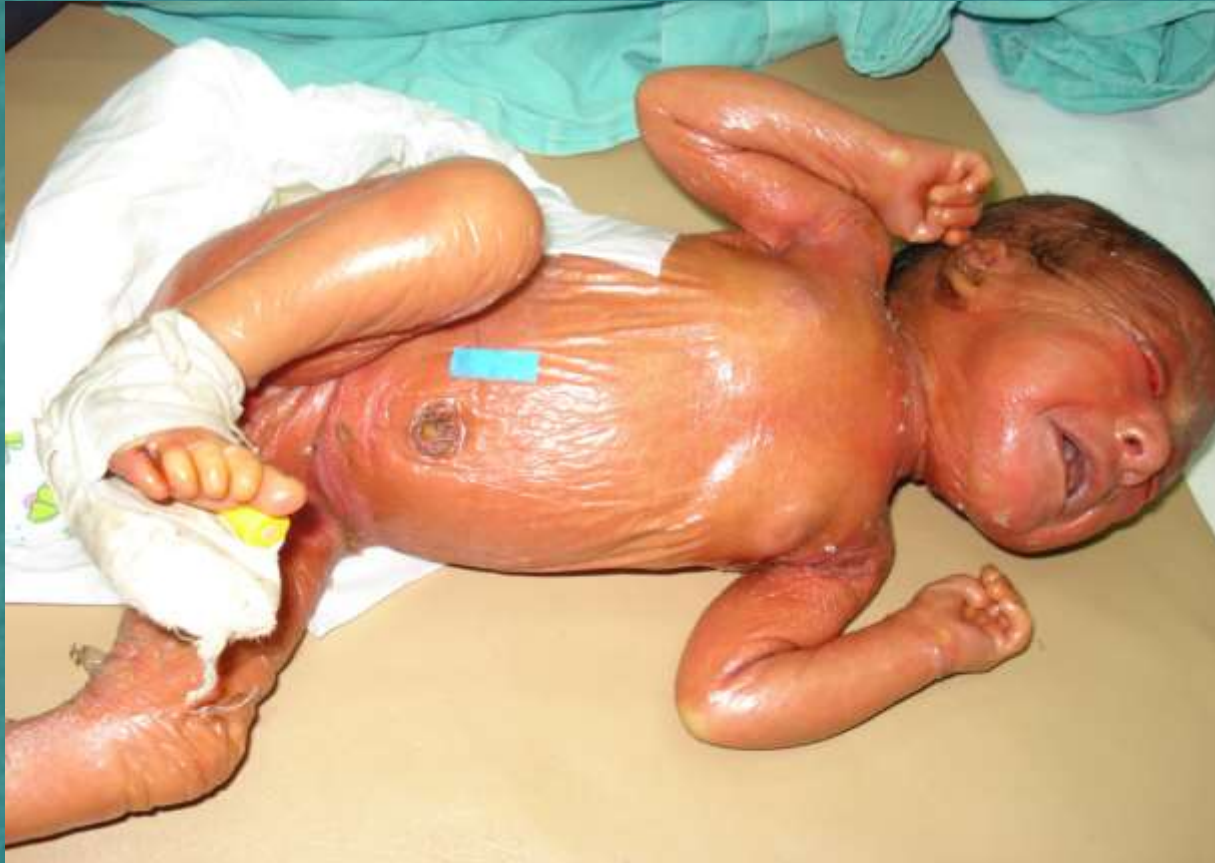# Collodion baby



# How will you manage this case?

- Special care nursery
- Cleaning
- Antiseptics
- Emollients
- Feeding
- Nasal obstruction
- Eye care
- Parent involvement & counseling

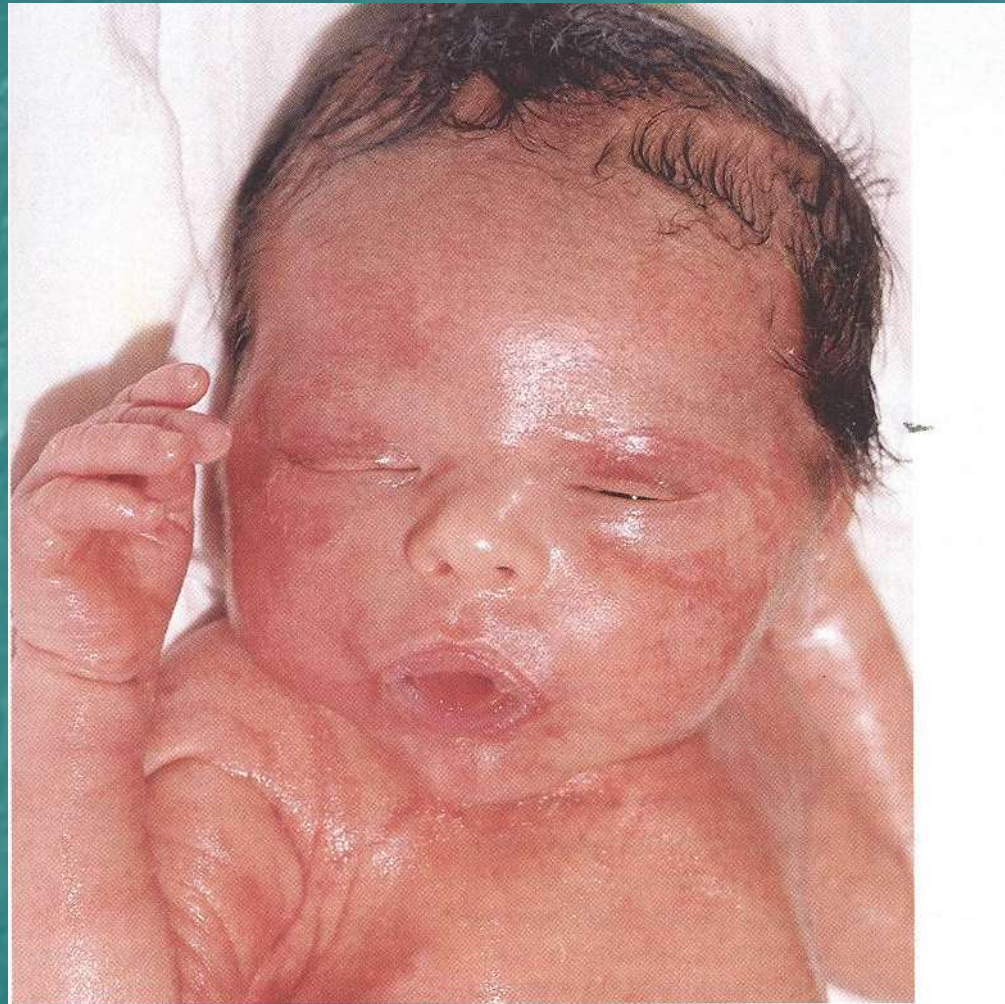# Collodion baby

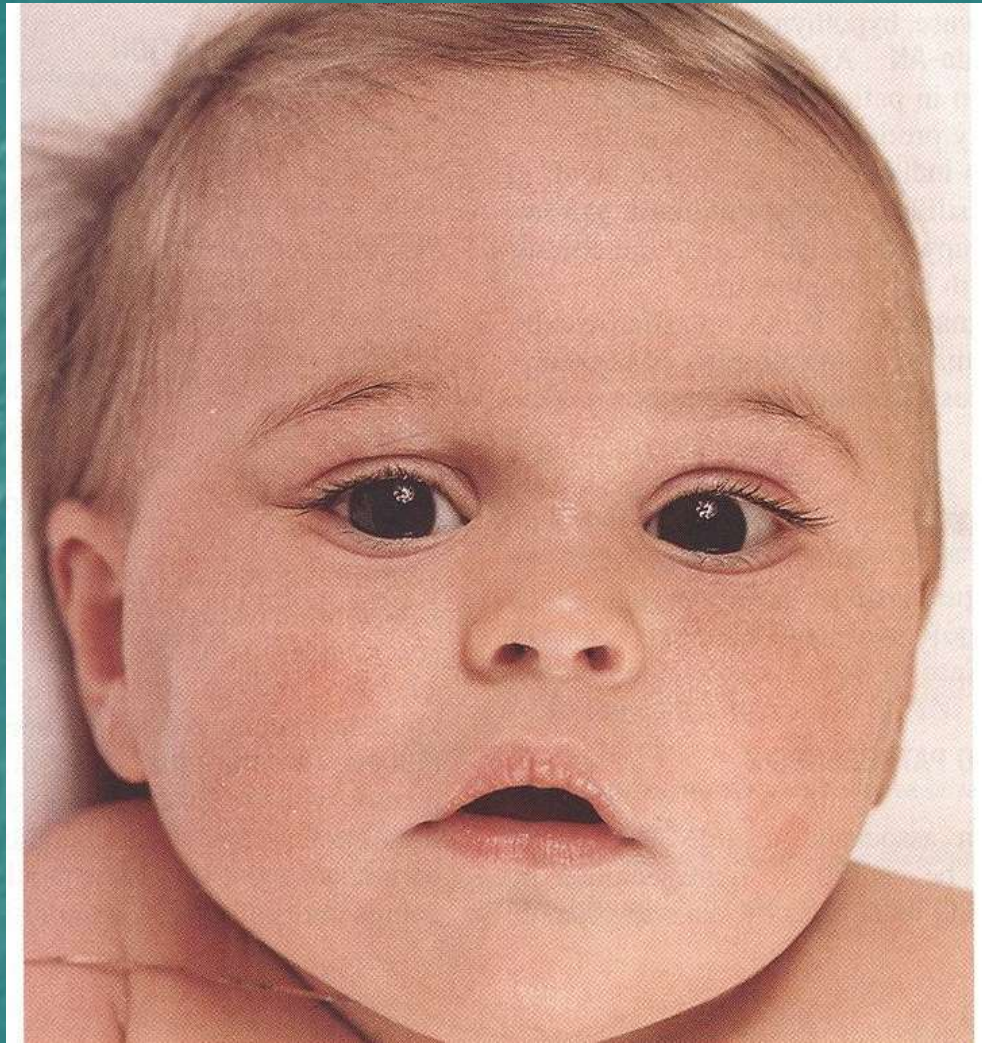


# What is fate/outcome of these babies?

- Non-bulbous Ichthyosiform Erythroderma
- Normal skin
- Lamellar Ichthyosis







**THANK YOU**