



# ***CASE PRESENTATION***

---

***BY***

***Dr Numair Ali sheikh***

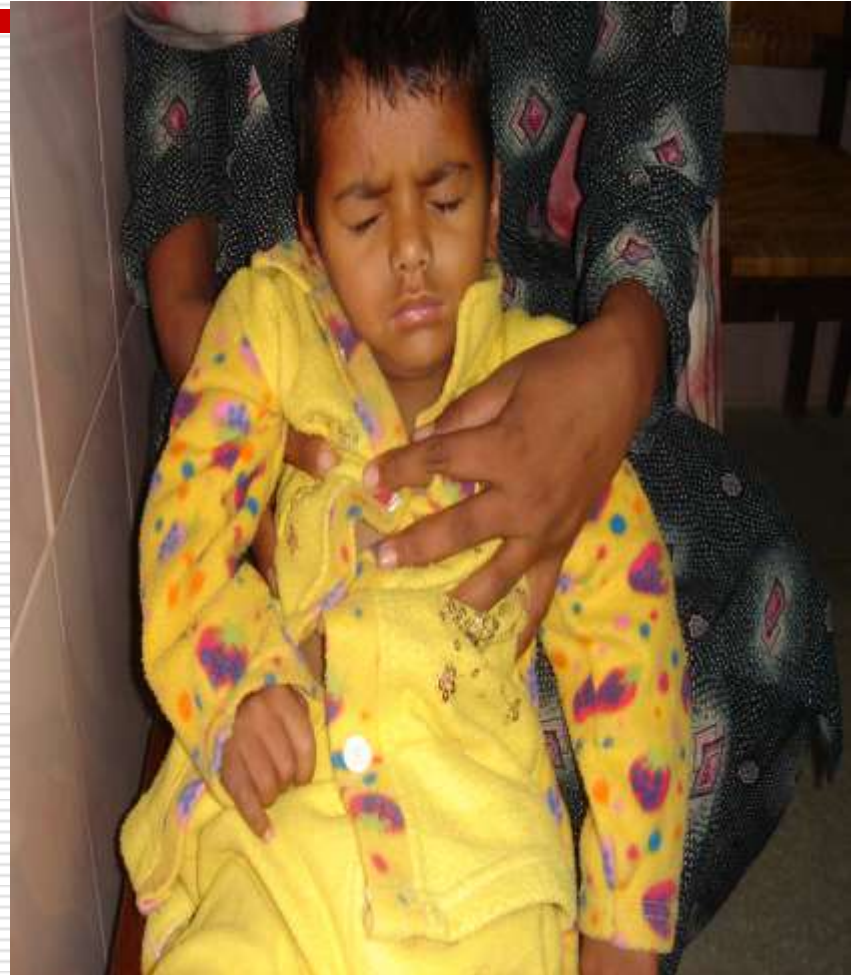***(FCPS PGT II)***

***Department Of Pediatrics***  
***BBH Rawalpindi***

# Patient Profile

---

- Name Aliha
- Age 05 yrs
- Sex Female
- Address Chakwal
- M.O.A OPD
- D.O.A 12-02-2010



# Presenting Complaints

---

Focal Fits &  
loss of consciousness - 01 day

---

# H/O PRESENT ILLNESS

---

Facial twitching of Lt. side of face

Unconsciousness lasting for one day

Slowly regained consciousness over the next 24 hrs

---

# **SYSTEMIC REVIEW**

---

- No H/O trauma or non accidental injury
  - No H/O of  
Cyanosis  
Rash  
Joint pains  
Lymphadenopathy  
Drug intake  
Haematuria or Bleeding
-

# PAST HISTORY

---

AT 6 months of age due to Lethargy & inability to hold neck – investigated

Diagnosed Hypothyroidism & thyroxine started

Remained well for next 1 ½ yrs

---

# At age 02 years

---

Fits & Weakness of Lt. side of body

Admitted in tertiary care hospital

CT scan showed Rt. sided ischemic infarct

Recovered partially ....

---

## **At age 03 yrs**

---

Second episode of similar kind

Fits & weakness of Rt side of the body

No proper treatment given

Condition showed limited improvement

---



# Birth History

---

SVD

Home delivered

No perinatal complications

---

# Developmental History

---

3MONTHS - Social smile

6MONTHS - Unable to hold neck

9MONTHS - Able to sit with support

---

# Developmental History -----

---

1Year - stand with support  
Pincer grasp

2Yrs - Able to climb up stairs  
Tower of six cubes  
Use cup and spoon  
Able to join two words

---

# Immunization History

---

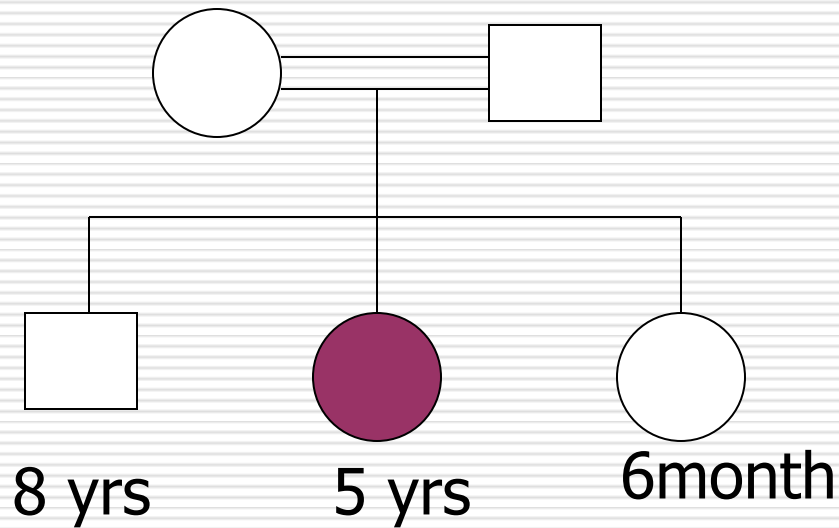
Vaccinated

BCG scar present

---

# FAMILY HISTORY

---



Elder brother and Younger sister - Hypothyroid

No family H/O similar illness or TB contact

---

# Socioeconomic History

---

Low socioeconomic group

Father Postman

---

# Examination

---

A young child uninterested in her surroundings

## Vitals

HR 78/min

RR 24/min

Temp. 98.6F

B.P 90/60mmHg (50<sup>th</sup> centile)

---

# Anthropometry

---

Ht. 87 cm < 5<sup>th</sup> Centile

Wt. 12 kg < 5<sup>th</sup> Centile

HC 47 cm < 2 standard deviations

---



# CNS

---

Conscious

Unable to comprehend

Aphasic

Cranial nerves : Intact

---

# CNS

---

Generalized hyperreflexia

Hyper-reflexia

Bilateral upgoing Planters

---

# CNS

---

Sensations of pain and temperature intact

No Cerebellar signs

No sign of meningeal irritation

---

# SYSTEMIC EXAMINATION

---

## □ GIT:

No hepatosplenomegaly

## □ RESPIRATORY SYSTEM :

Normal Vesicular breathing

## □ CVS :

S1 + S2 + no added sound

---

# Provisional Diagnosis

---

Repeated CVA 's  
(Ischemic infarcts)

---

# D/D of Repeated CVA

---

## **Hematological**

- Sickle cell disease
- Protein C/S deficiency

## **Metabolic**

- Homocysteinemia
- Hypercholesterolemia

## **Vascular**

- AV malformations
- Carotid artery aneurysms
- Moyamoya disease

## **Connective tissue**

- Polyarteritis nodosa
  - SLE
-

# Investigations

---

Blood CP	Normal
PT/APTT	Normal
LFT	Normal
RFT	Normal
Lipid profile	Normal
Hb Electrophoresis	Normal

---

# Investigations

---

Homocystein level 9.79micmol/L (N)

ANA Negative

Protein C/S Normal

Antithrombin III Normal

Echocardiography Normal

Doppler Scan of Carotid arteries Normal

---



# CT Scan Brain

---

Lt. Frontoparietal & Rt. Parietal ischemic Infarcts

Basal ganglia & periventricular calcifications

---

# MRI/MRA

---

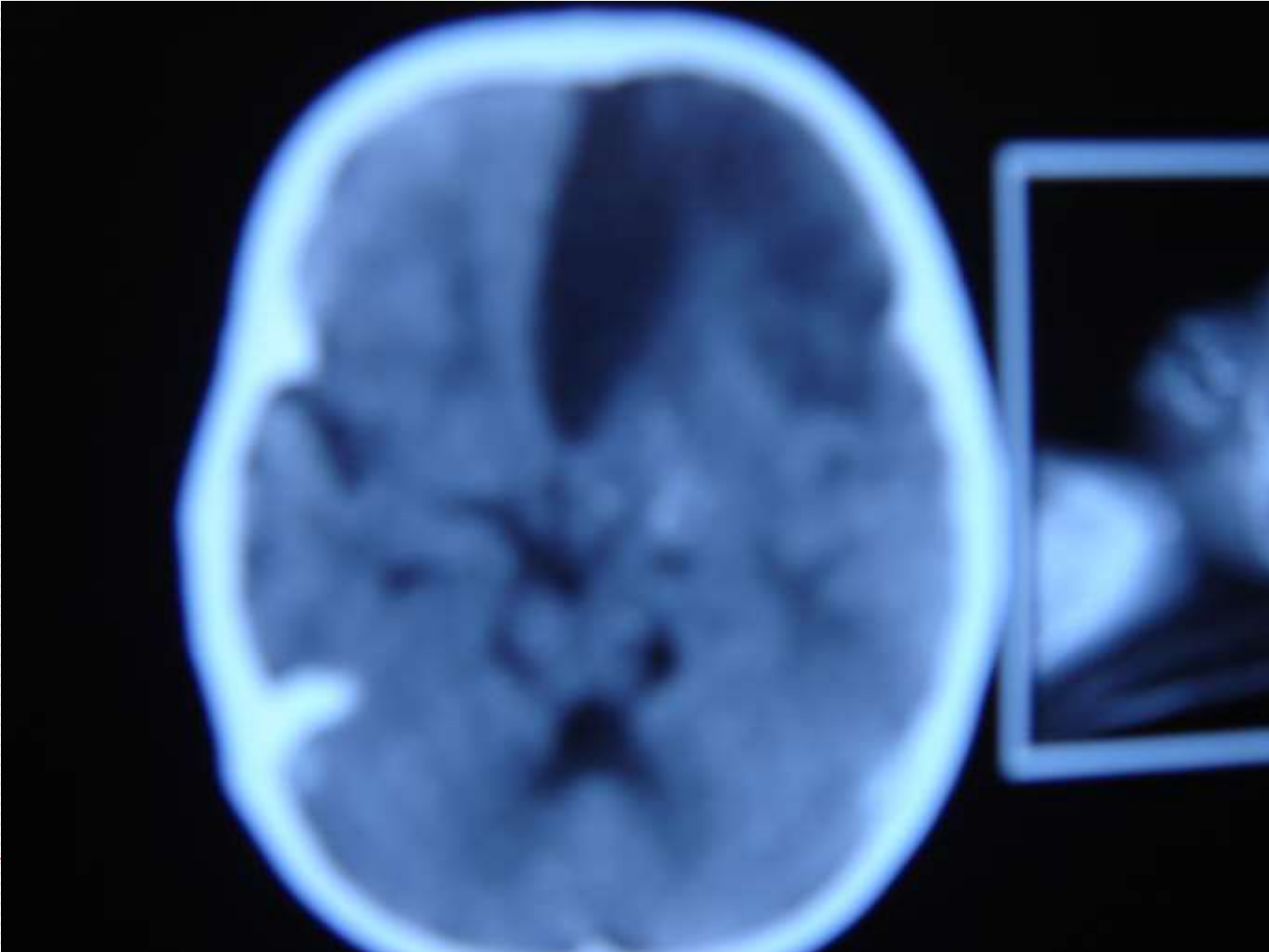
Narrowing of vessels of circle of willis

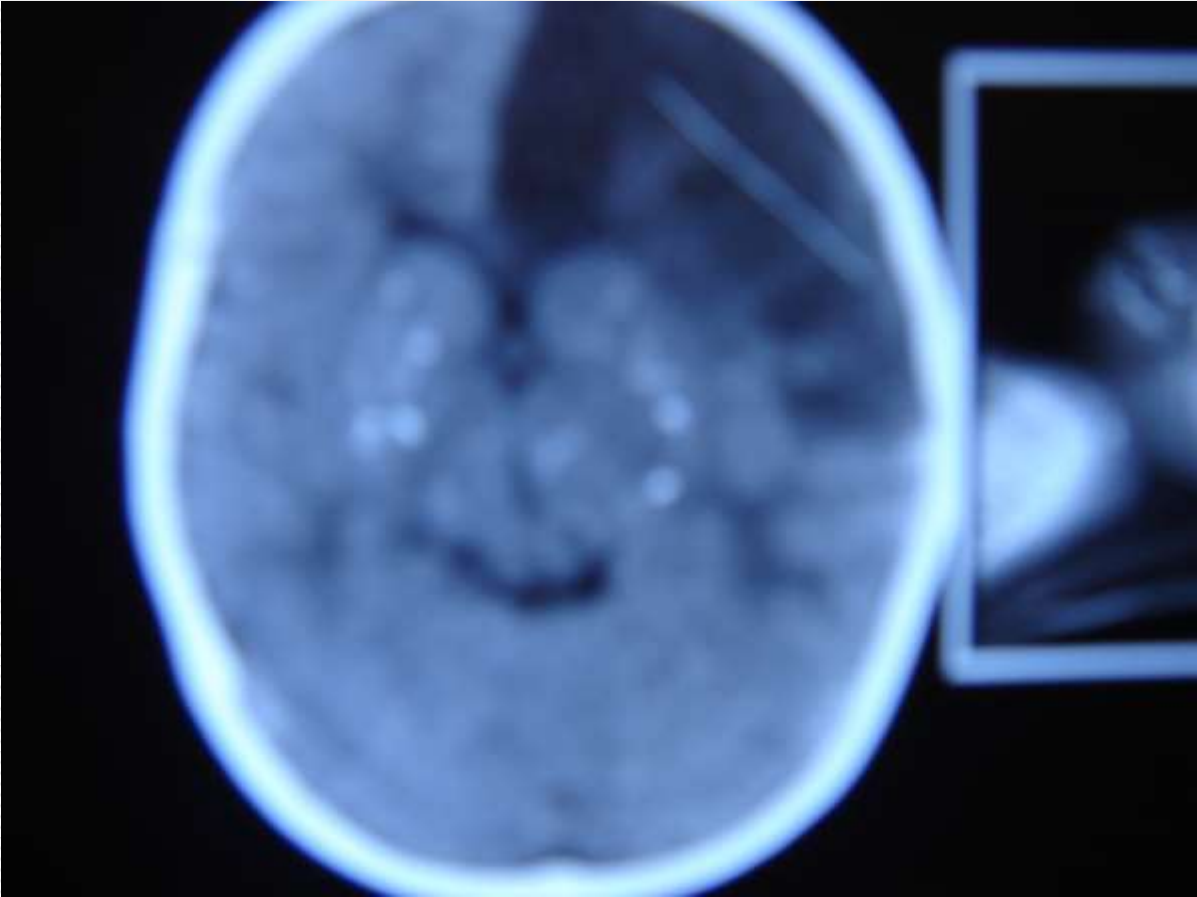
Multiple collateral formation

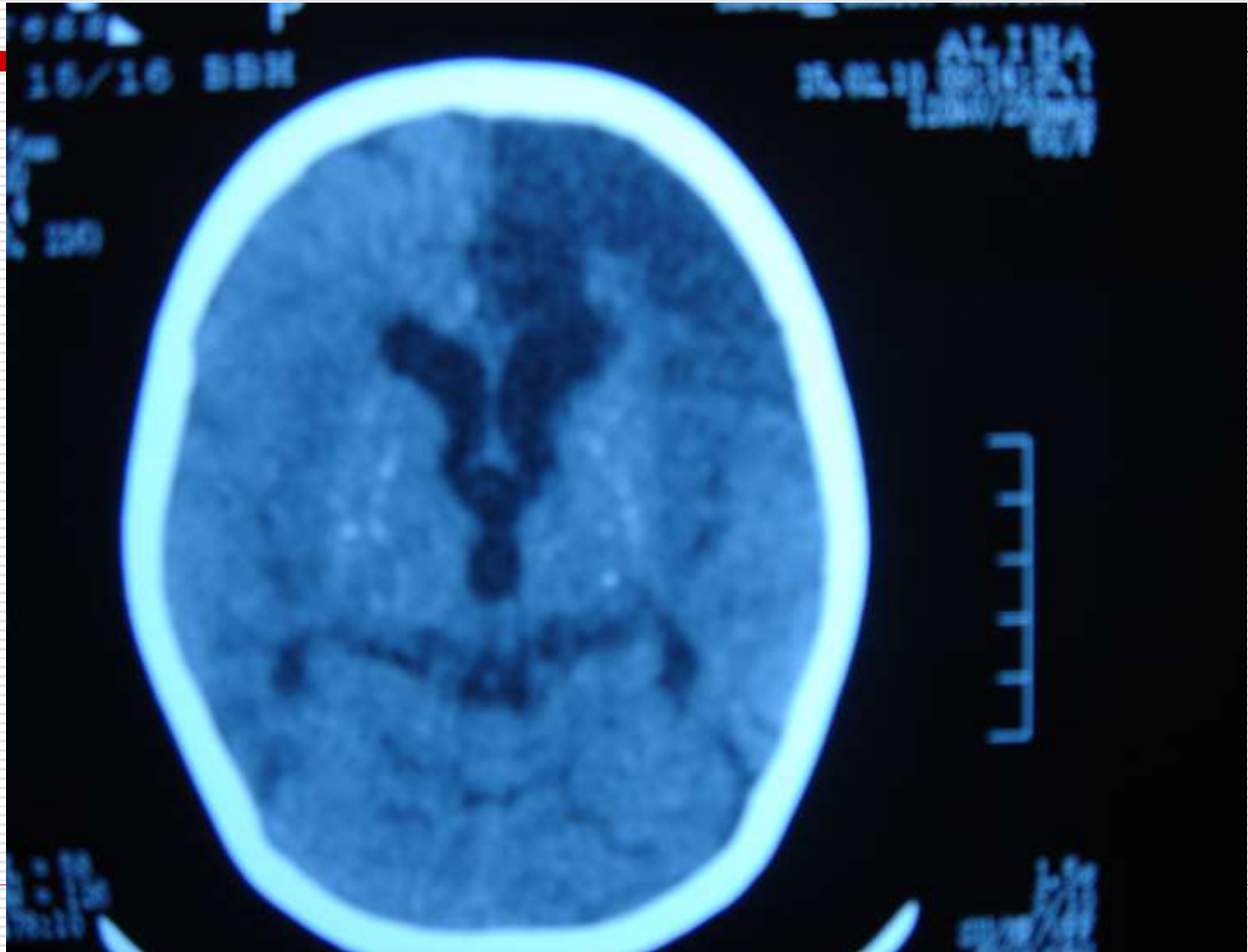
*PUFF OF SMOKE* appearance

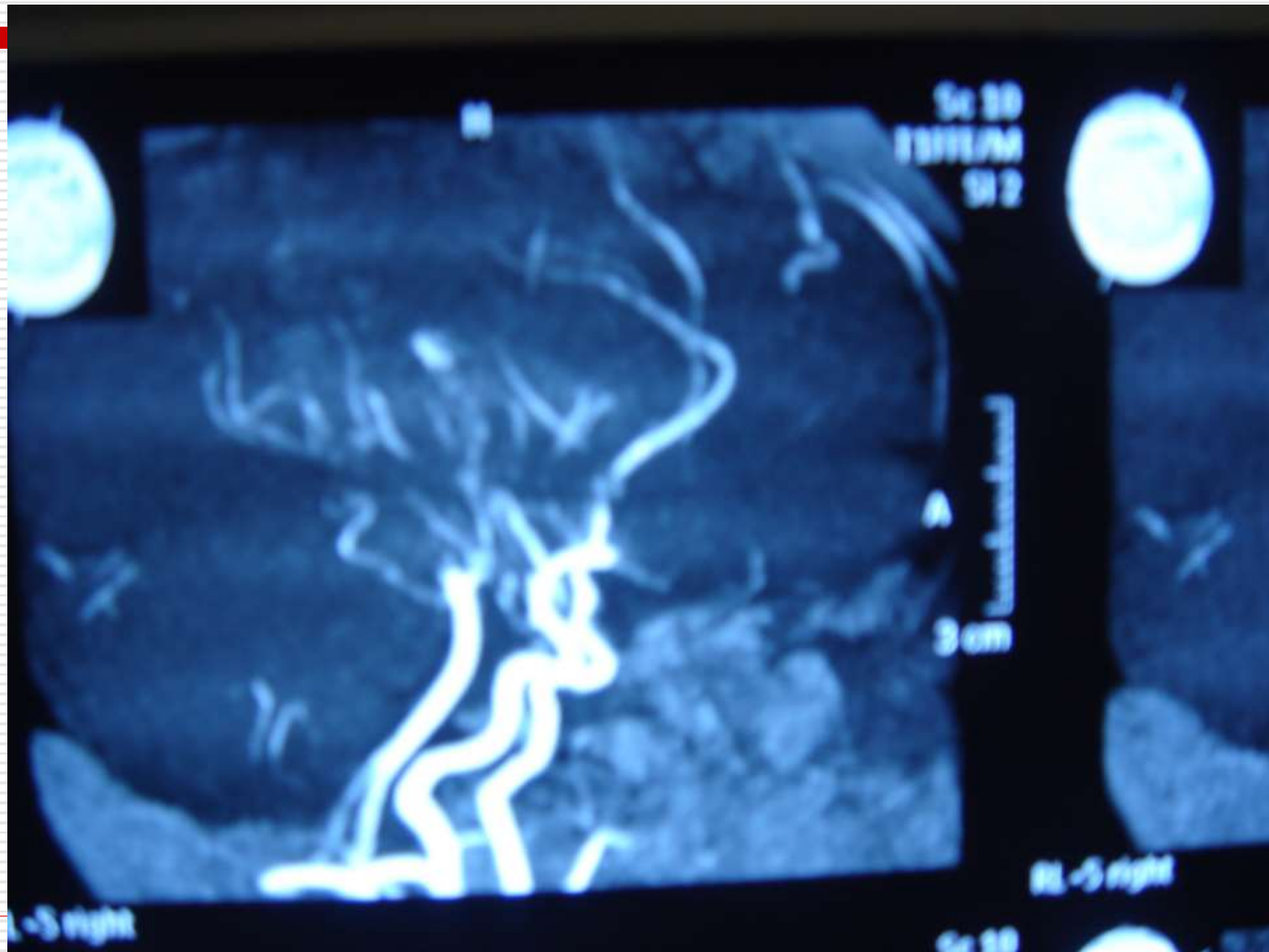
suggestive of **Moyamoya disease**

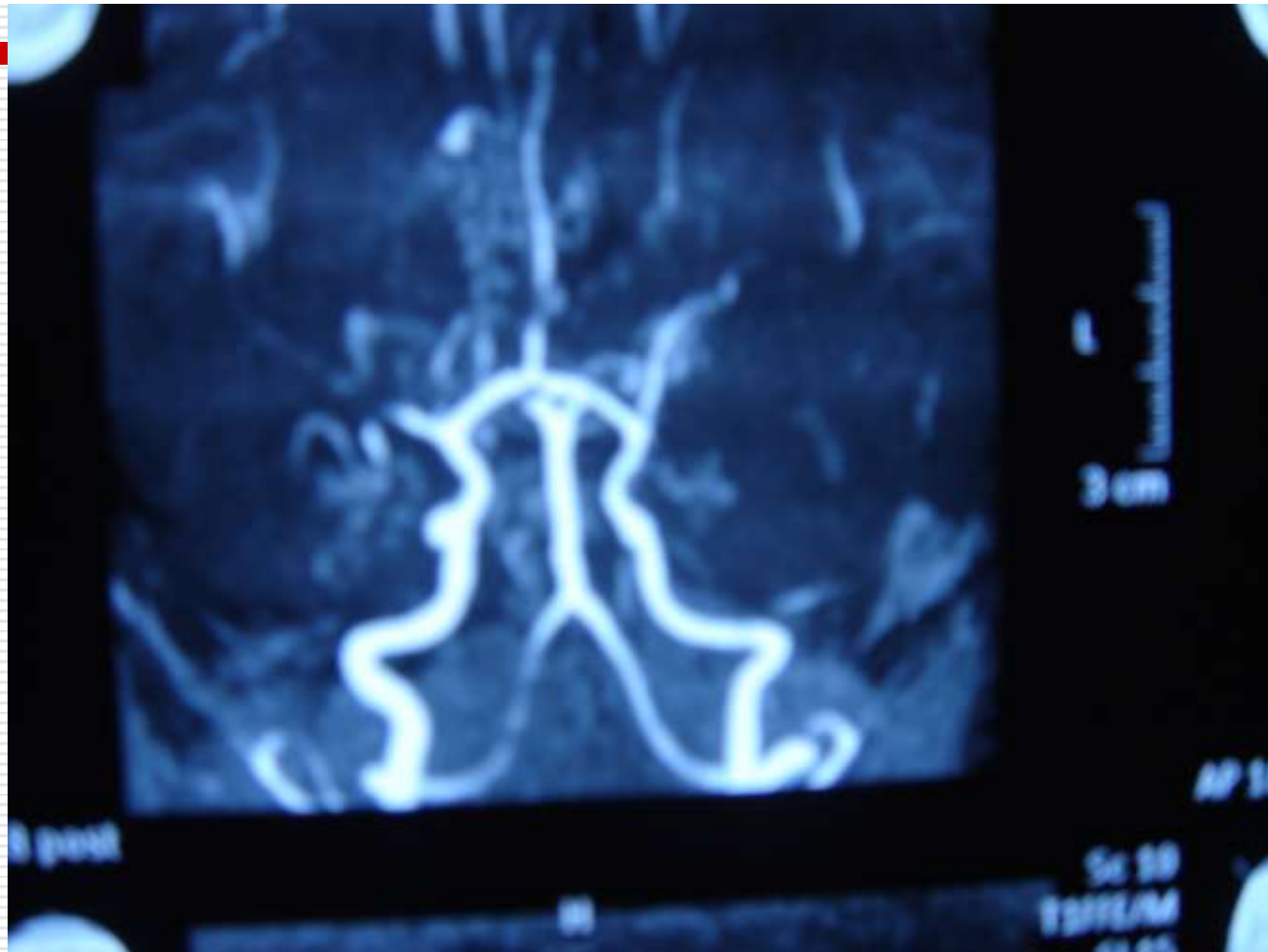
---











---

# Final Diagnosis

**Moyamoya Disease**

---



# TREATMENT

---

- Supportive
  - Nutritional Rehabilitation
  - Physiotherapy
  - Neurosurgical Intervention
-

# Moyamoya Disease

---

- progressive disease
  - distal internal carotid arteries and their major branches
  - characterized by occlusion
  - show intimal proliferation
  - A characteristic finding
    - formation of a collateral network of blood vessels at the base of brain with an unusual angiographic appearance described as a **PUFF OF SMOKE**
-

---

## **Incidence**

1/100,000

**Male to Female Ratio**

1:1.65

**Mean age of Diagnosis**

05years

---

# Presentation

---

Children afflicted with Moyamoya disease usually present with strokes, TIAs, which may alternate sides and slowly progressive cognitive decline

---

**Pathogenesis**    Unknown

---

## **Treatment**

1. Superficial temporal to middle cerebral artery bypass.
  2. Encephalomyosynangiosis , a procedure that involves laying the temporalis muscle over the surface of the brain
-

# Prognosis

---

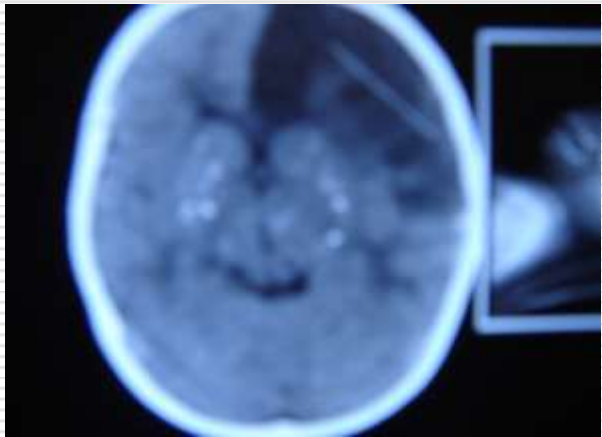
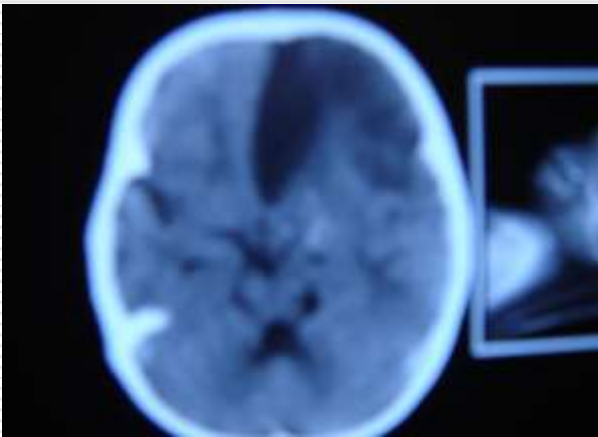
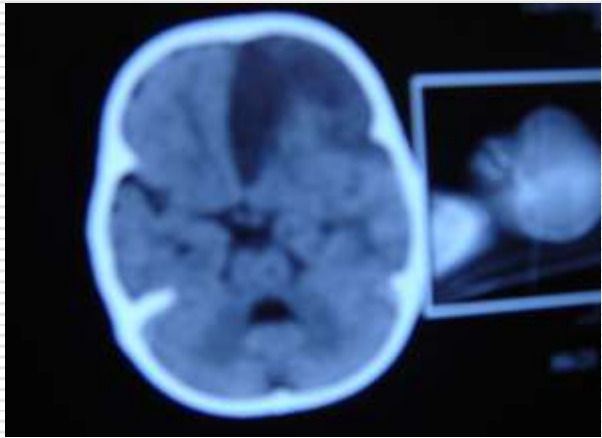
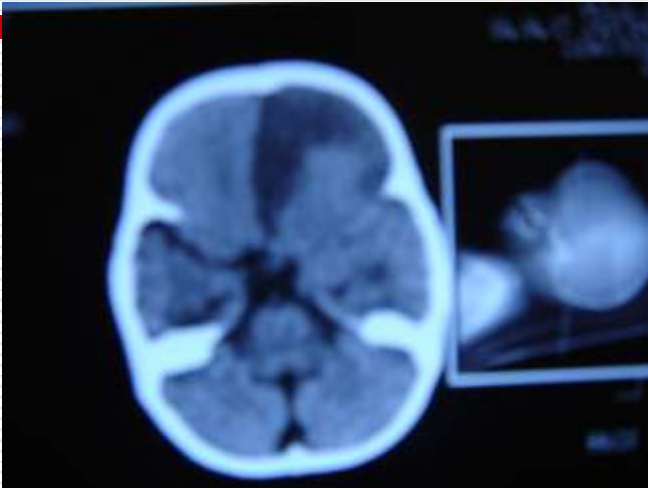
Operative angiograms showed 100% graft patency and successful revascularization of the MCA distribution in over 90% of the cases.

---

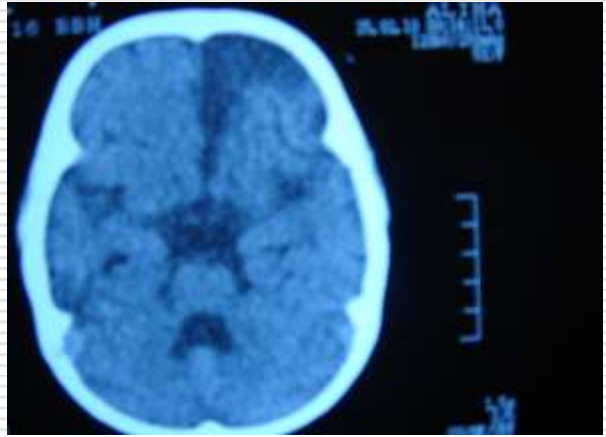
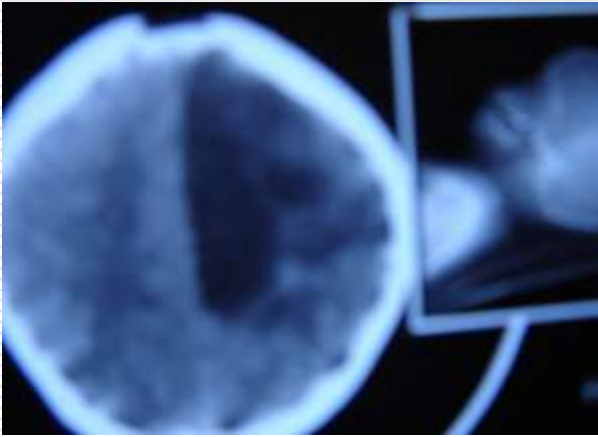
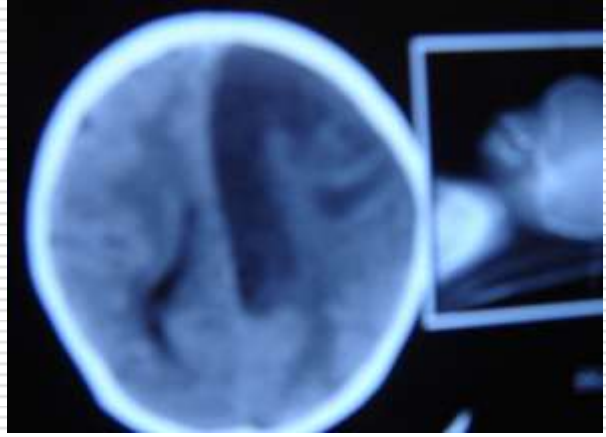
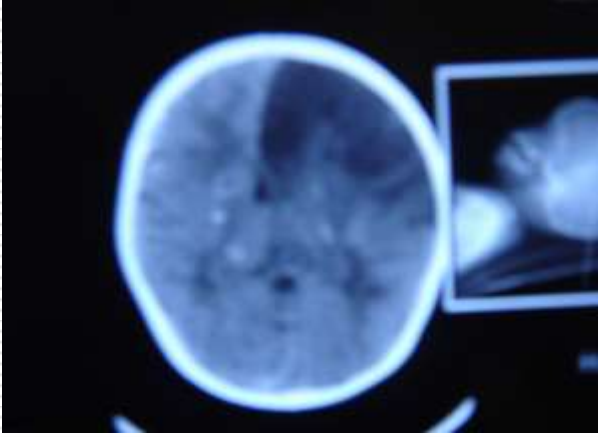
---

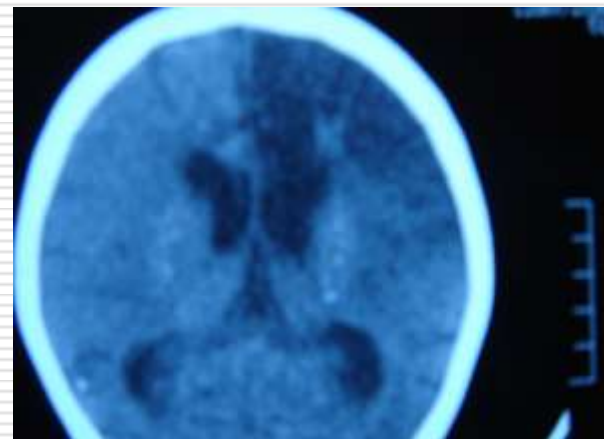
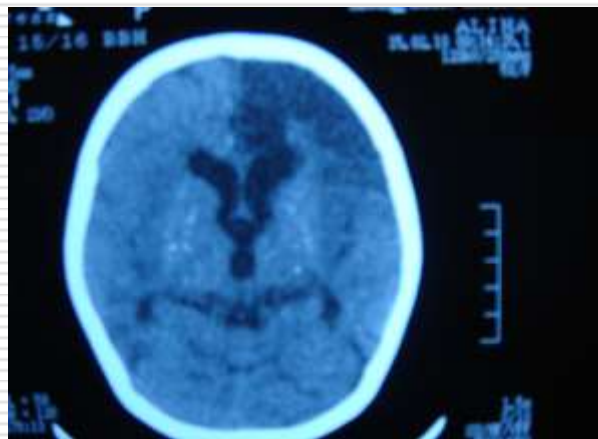
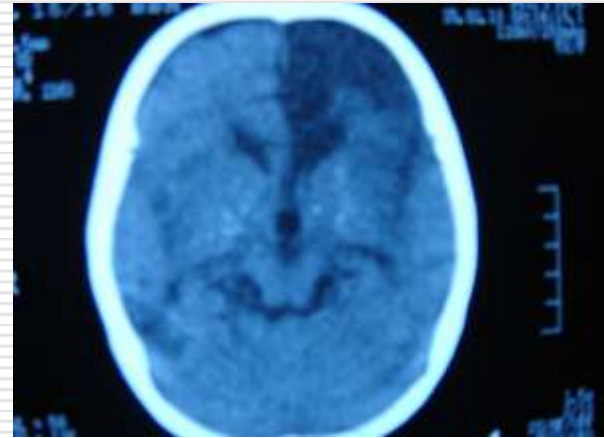
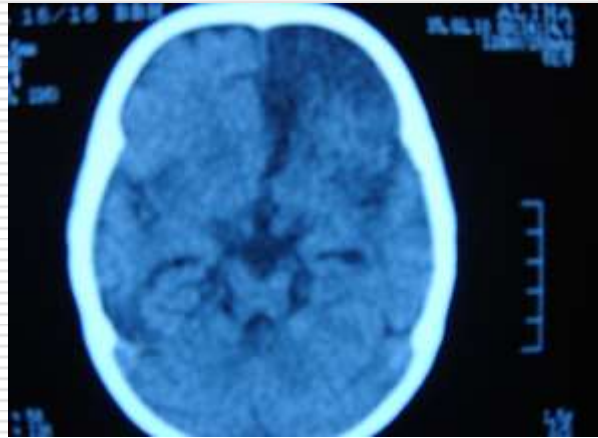
**Thank You**

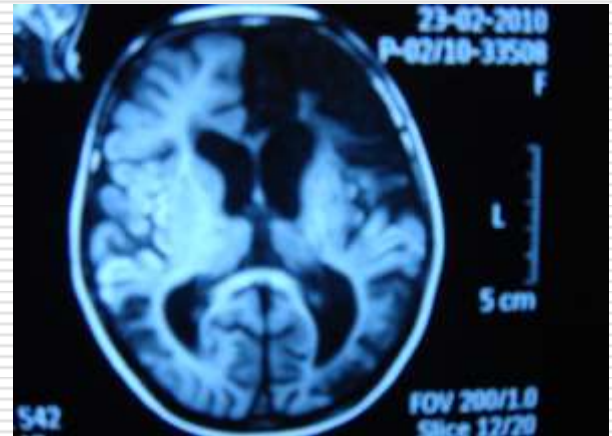
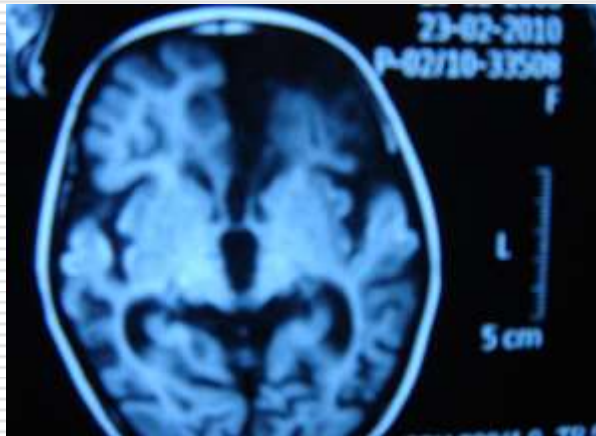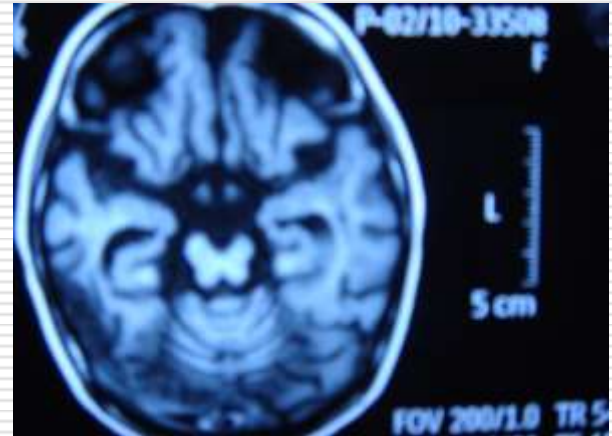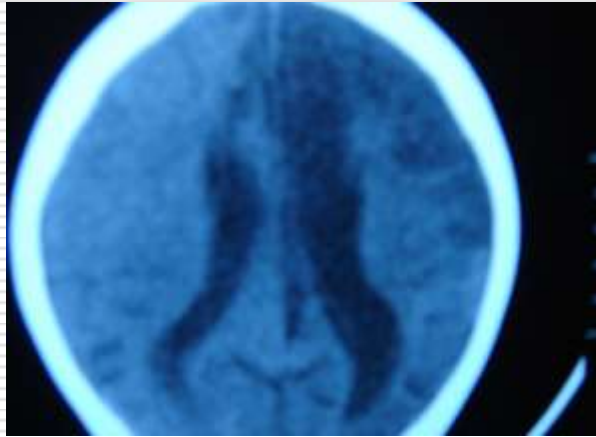
---

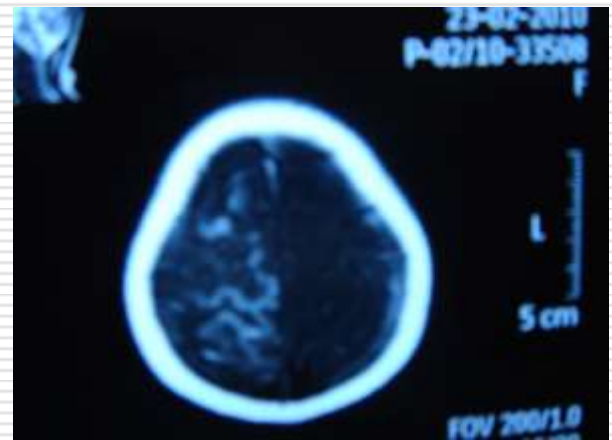
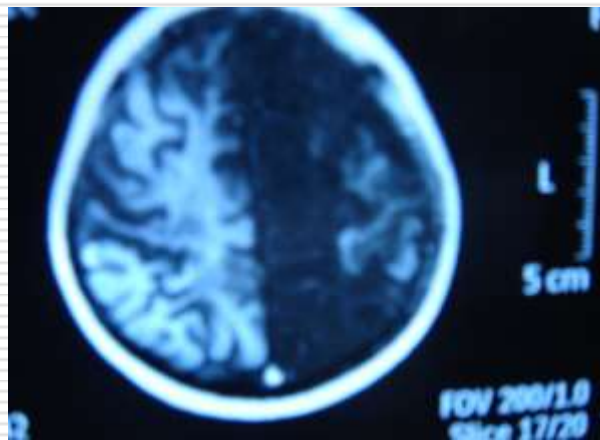
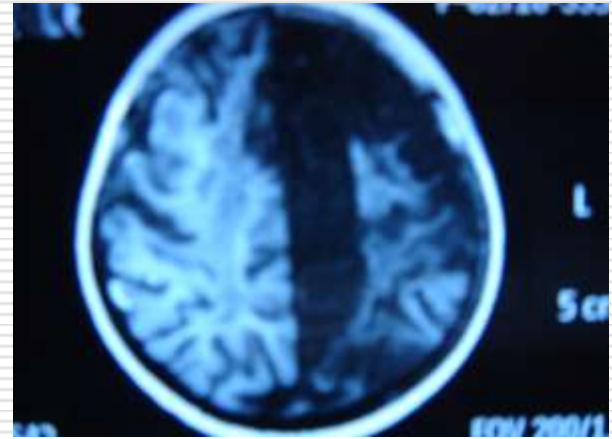
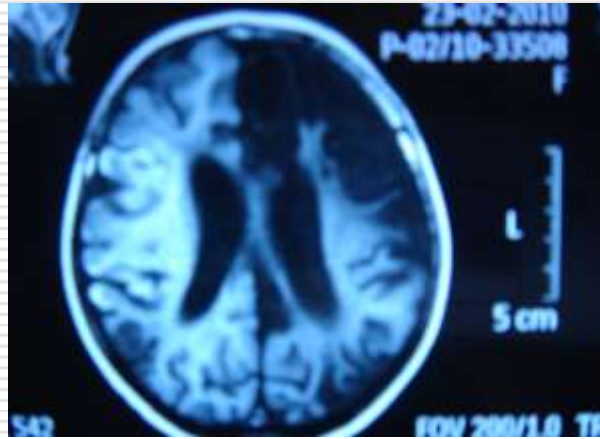




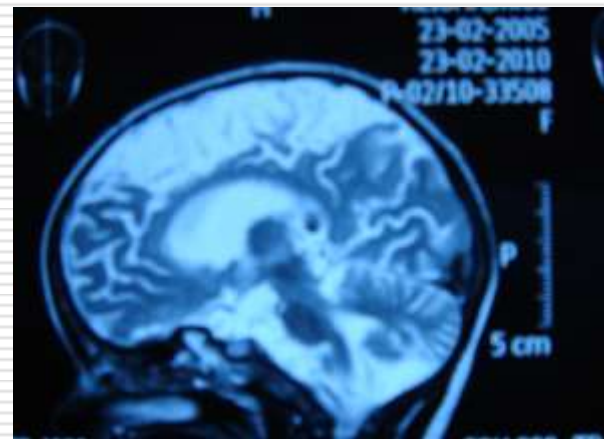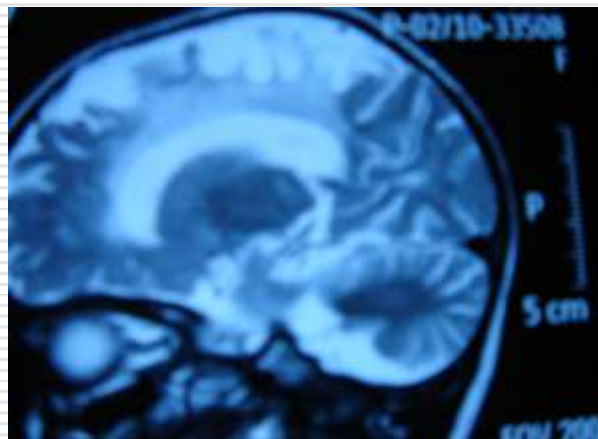
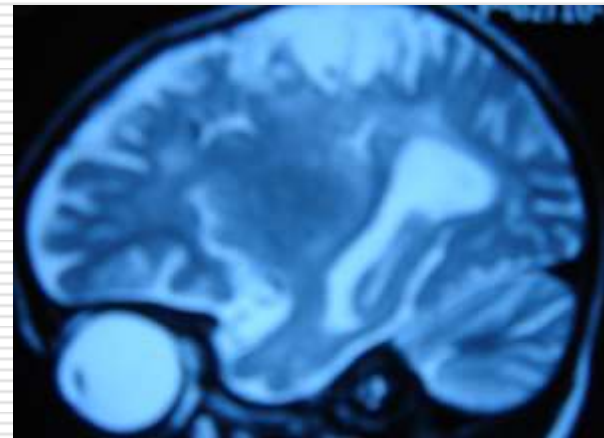
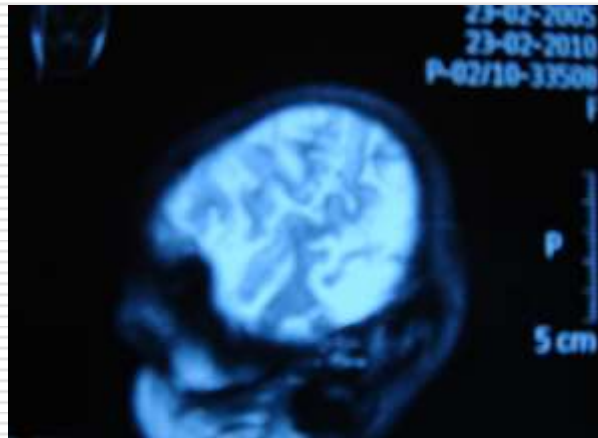


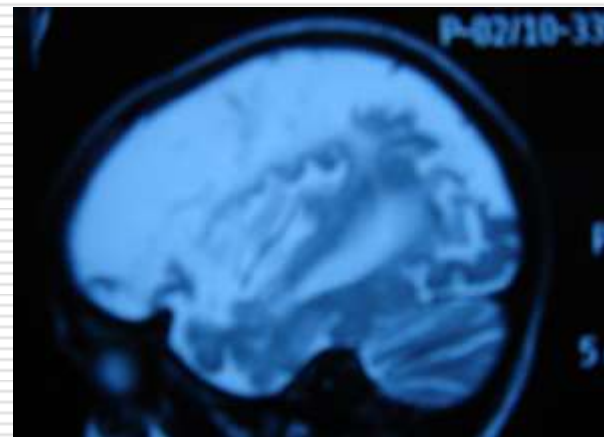
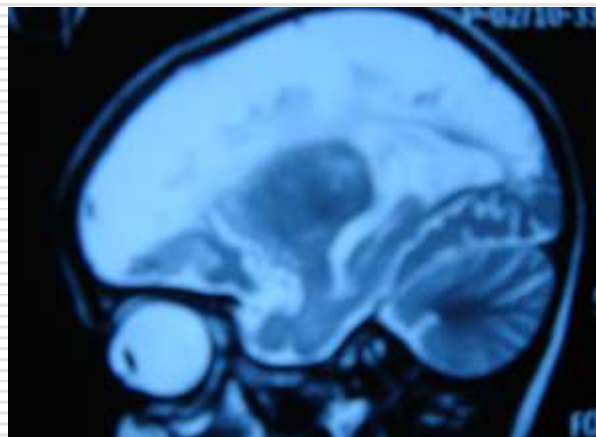
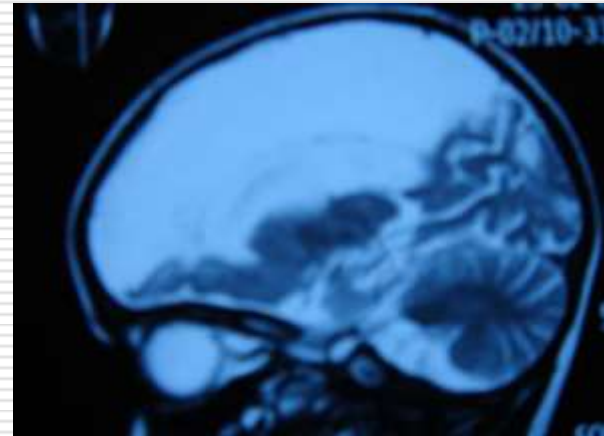
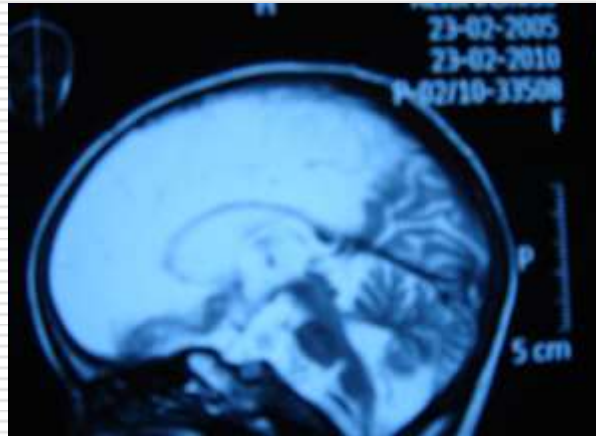


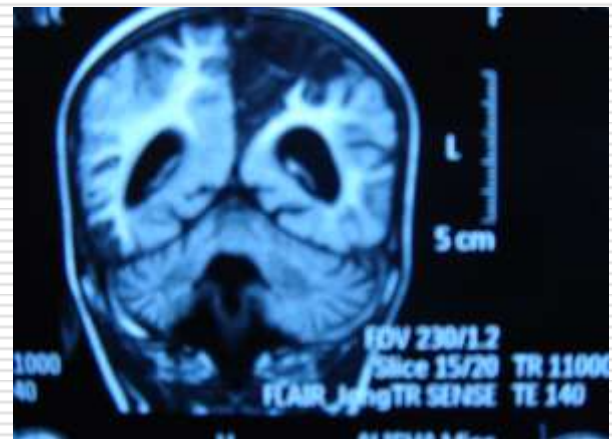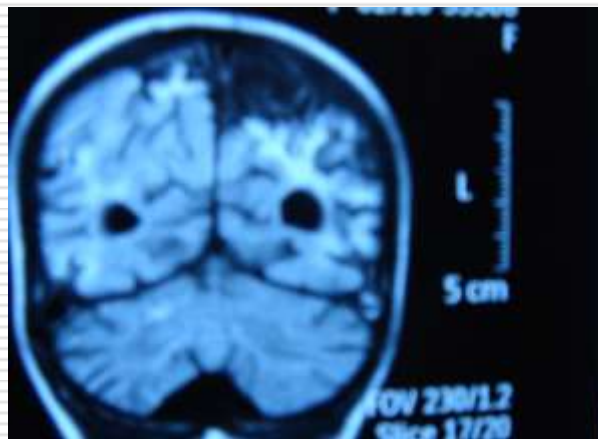
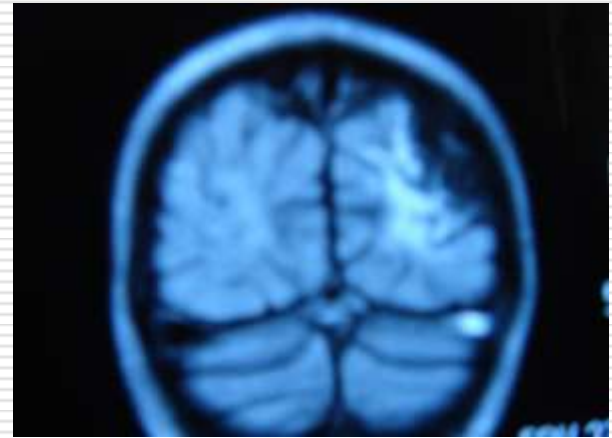
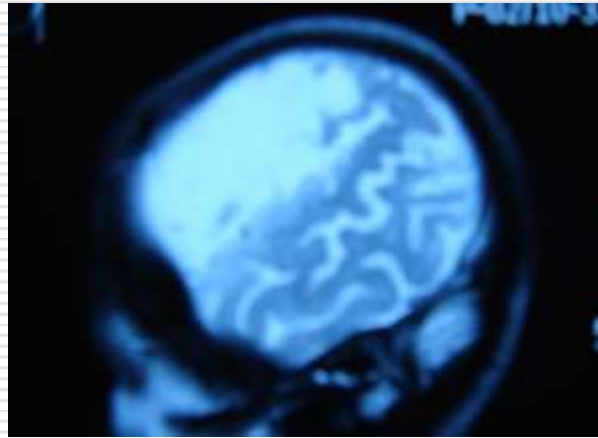


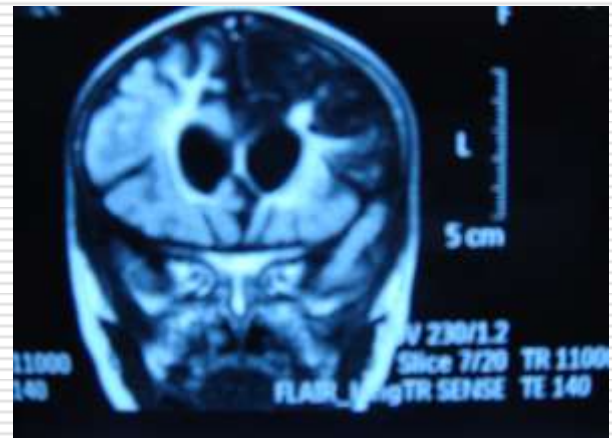
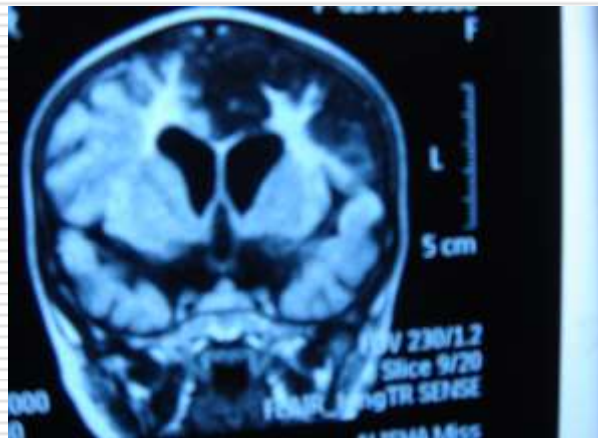
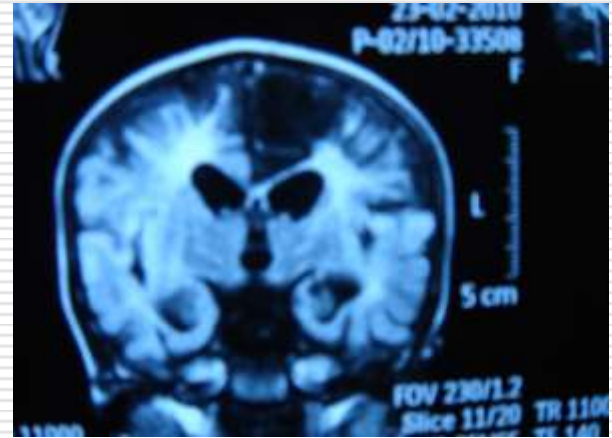
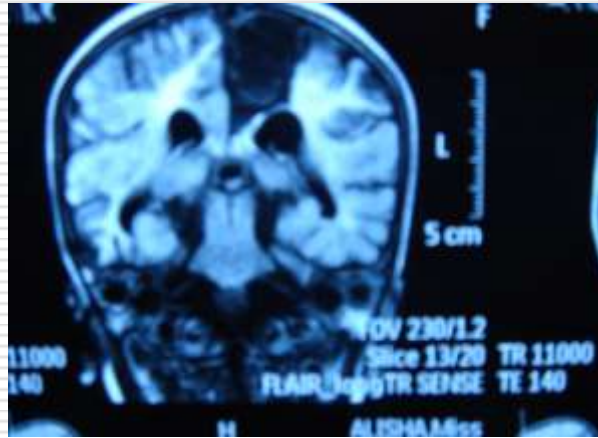




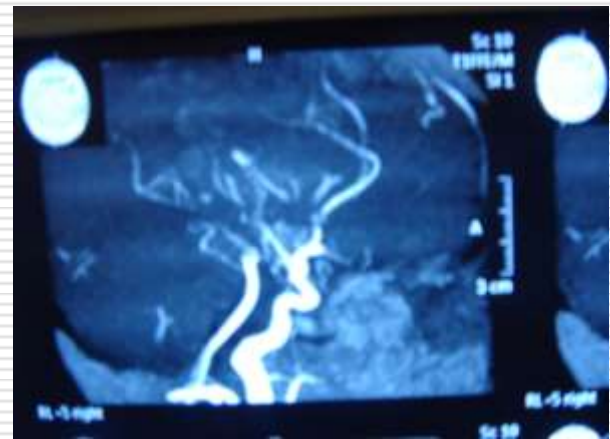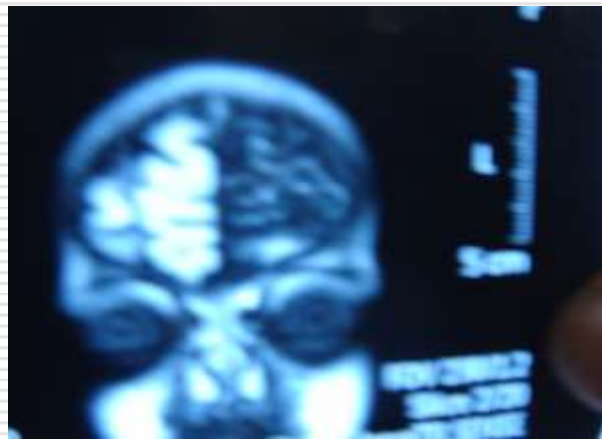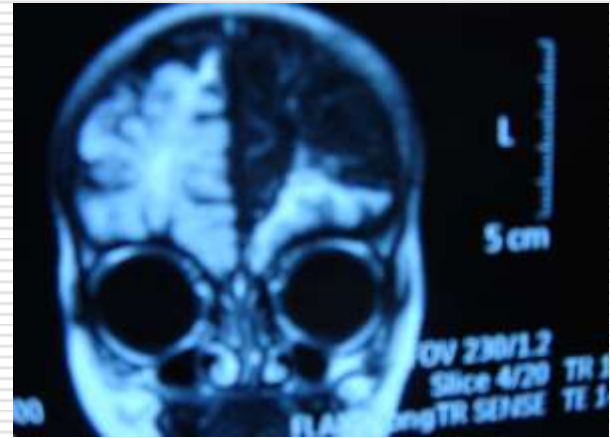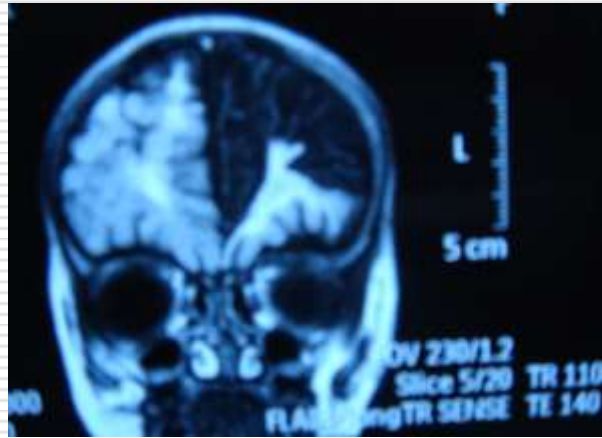


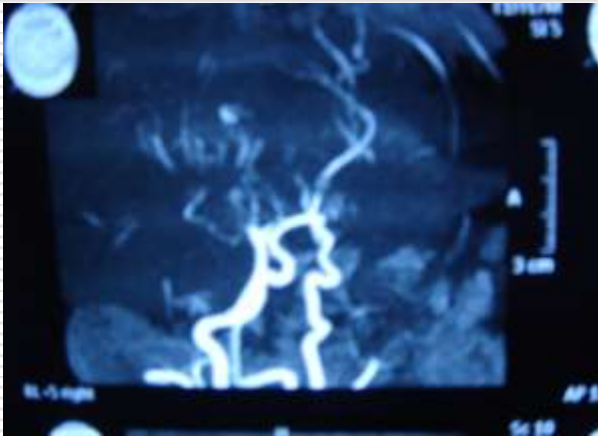
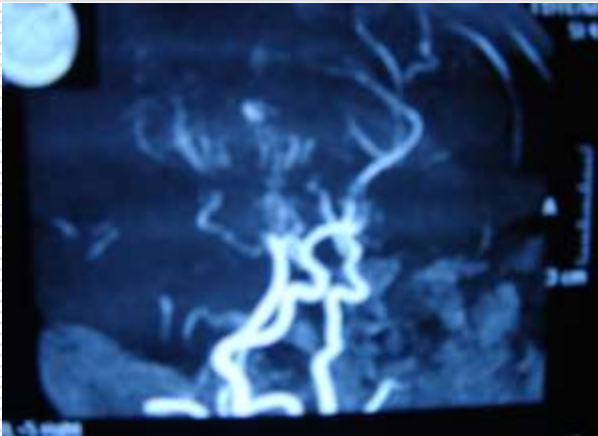


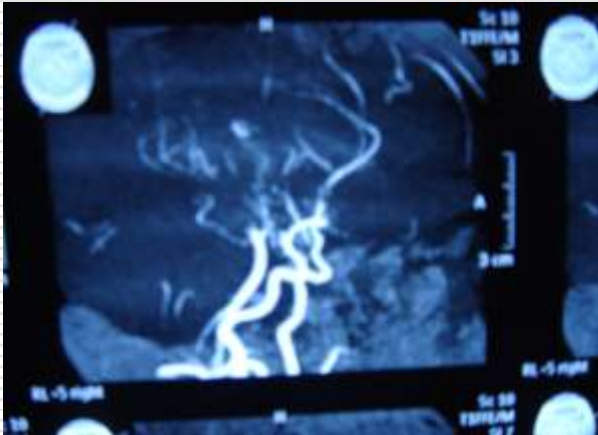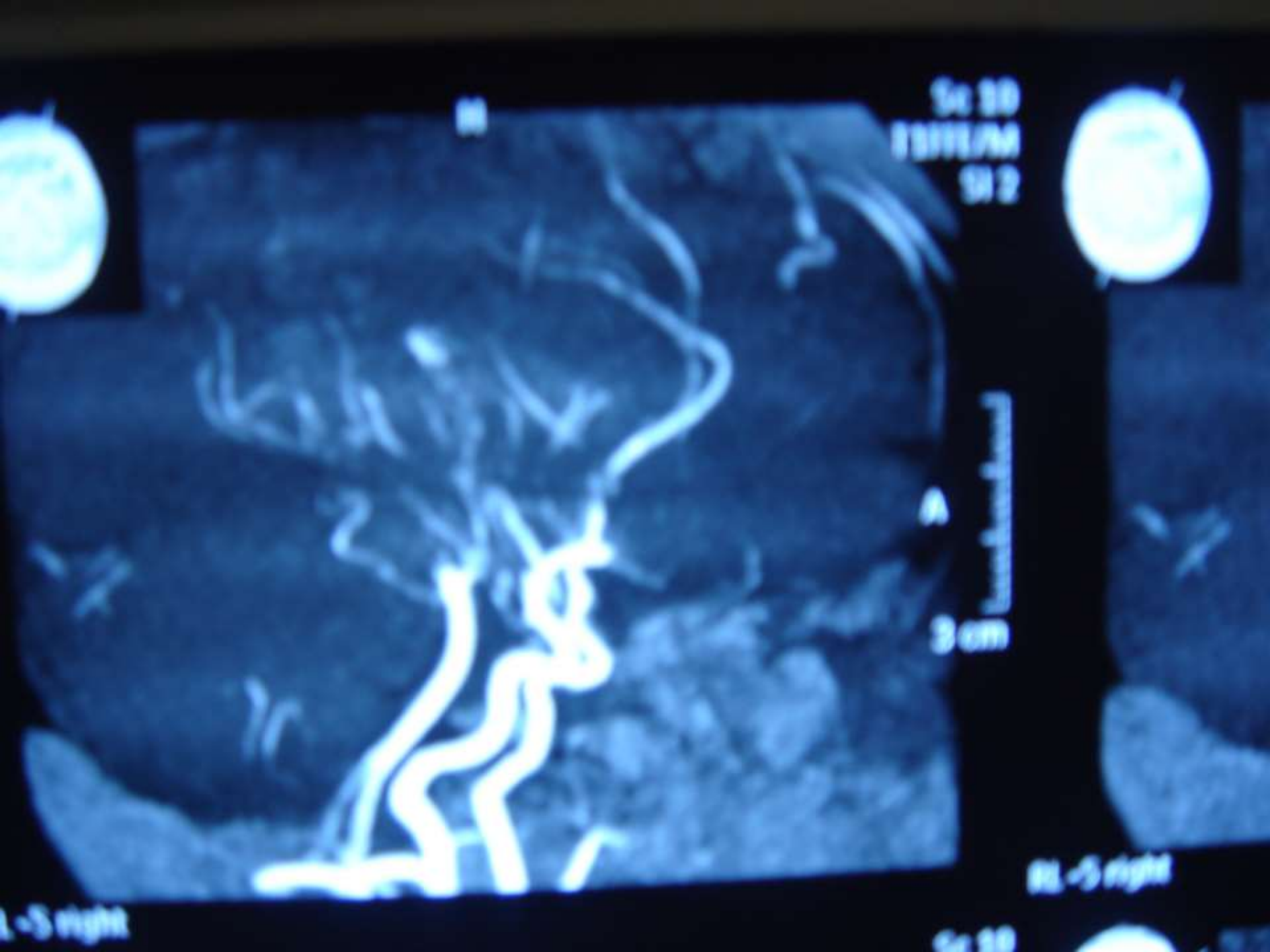












Sc 30

1000/100

50.2

2 cm

2 cm

R-5 right

L-5 right

Sc 30

