

# Diseases of External Ear

Dr. Mahboob Yazdani Khan  
Assistant Professor E.N.T.  
Rawalpindi Medical College /  
Benazir Bhutto Hospital

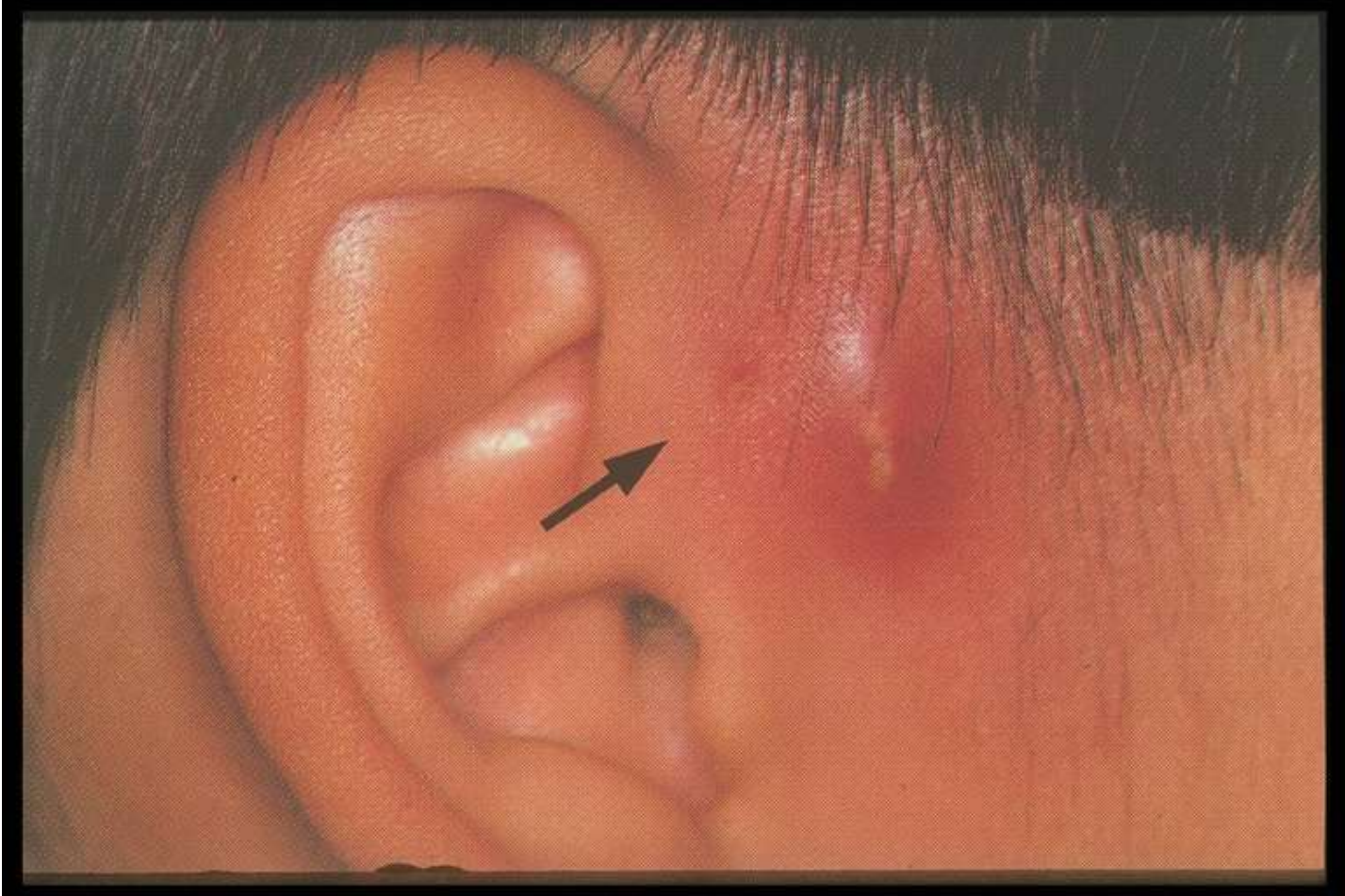
- Diseases Of External ear are classified as follows
- 1-congenital
- 2-inflammatory
- 3-Traumatic
- 4-Neoplastic

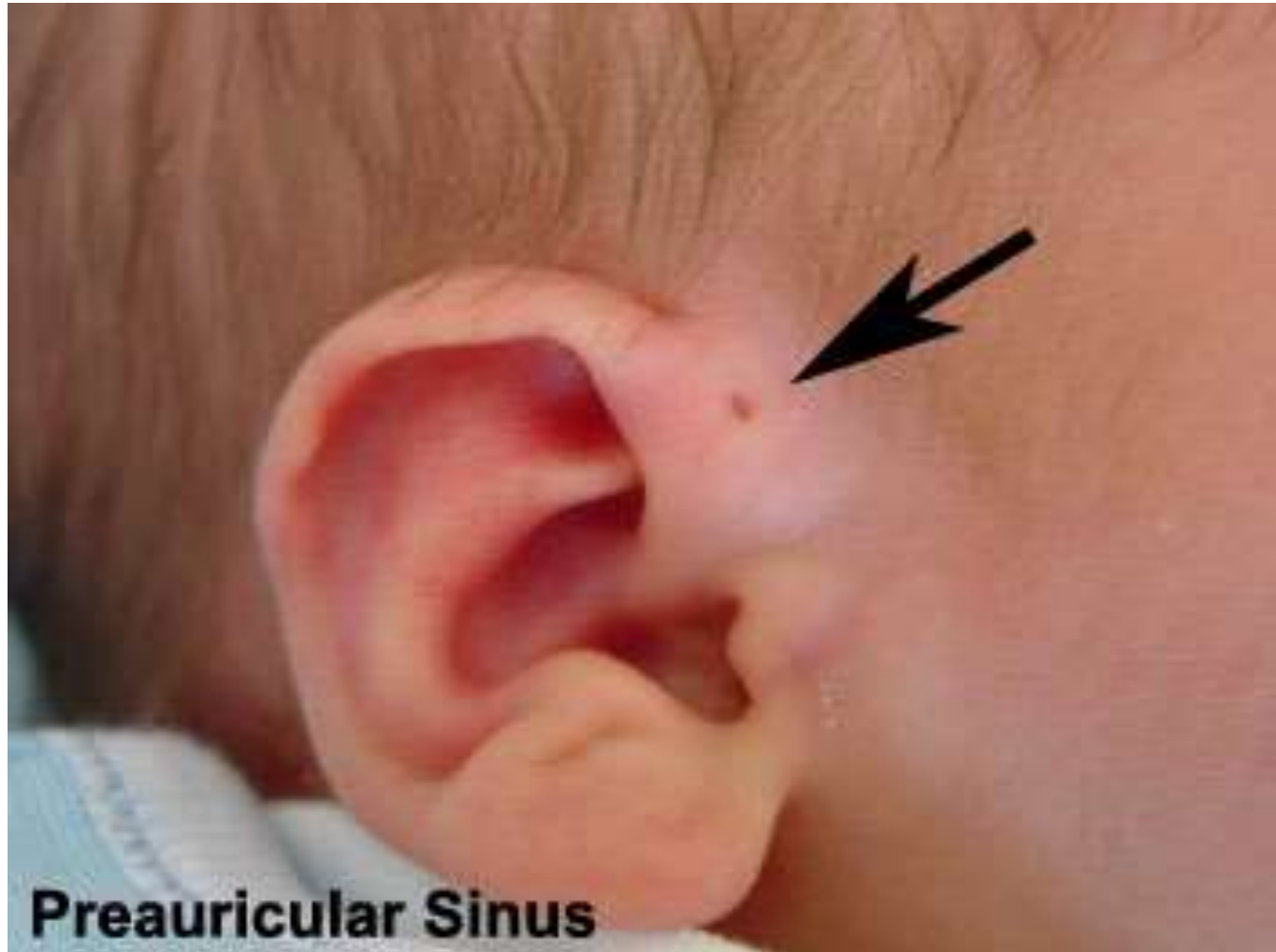## CONGENITAL

- 1- Preauricular sinus
- 2- Congenital swellings (Pinna)
- 3- Collaural fistula
- 4- Congenital anomalies (Pinna)
- 5- Atresia external canal
- 6- Congenital tumors of external canal

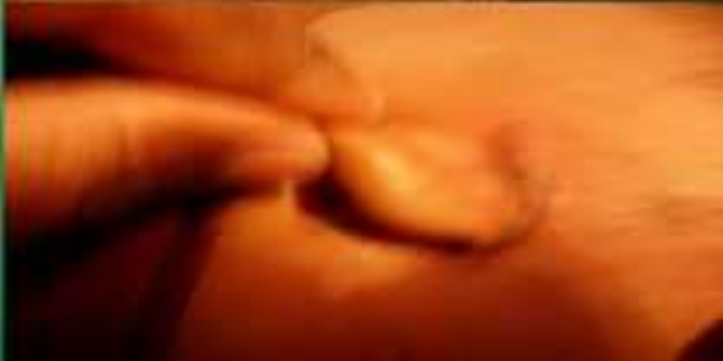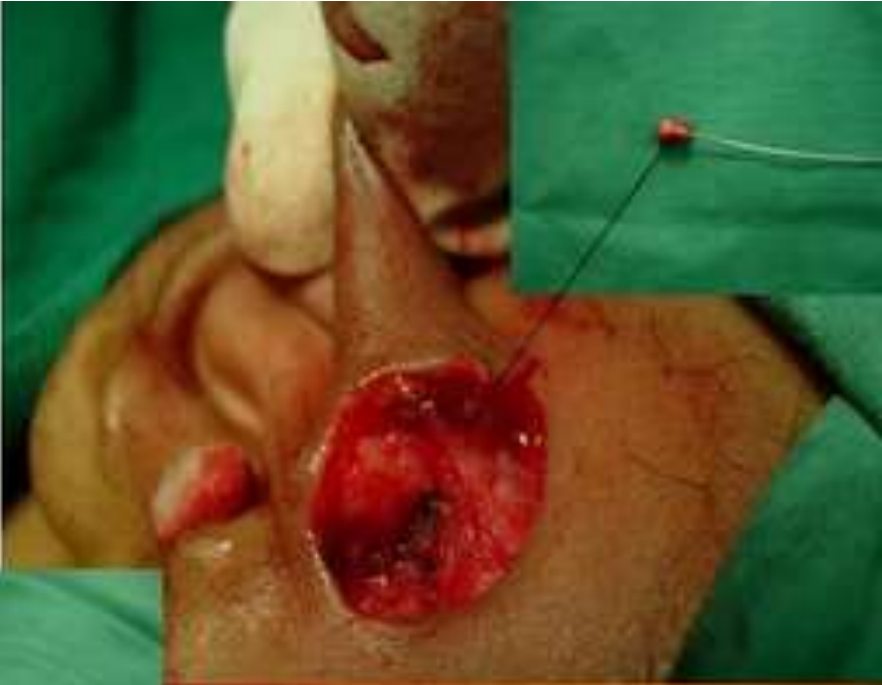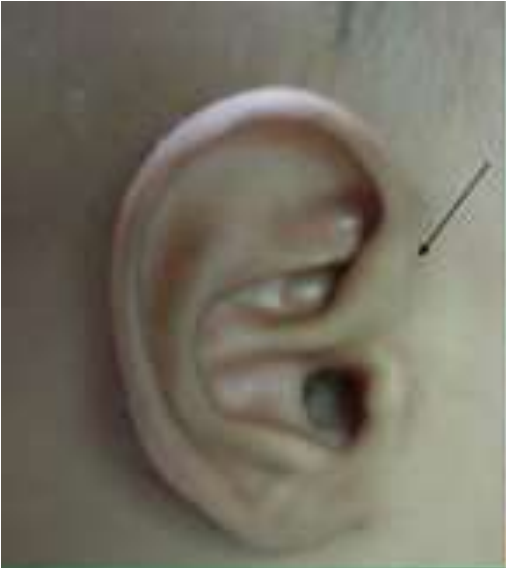# PRE AURICULAR SINUS

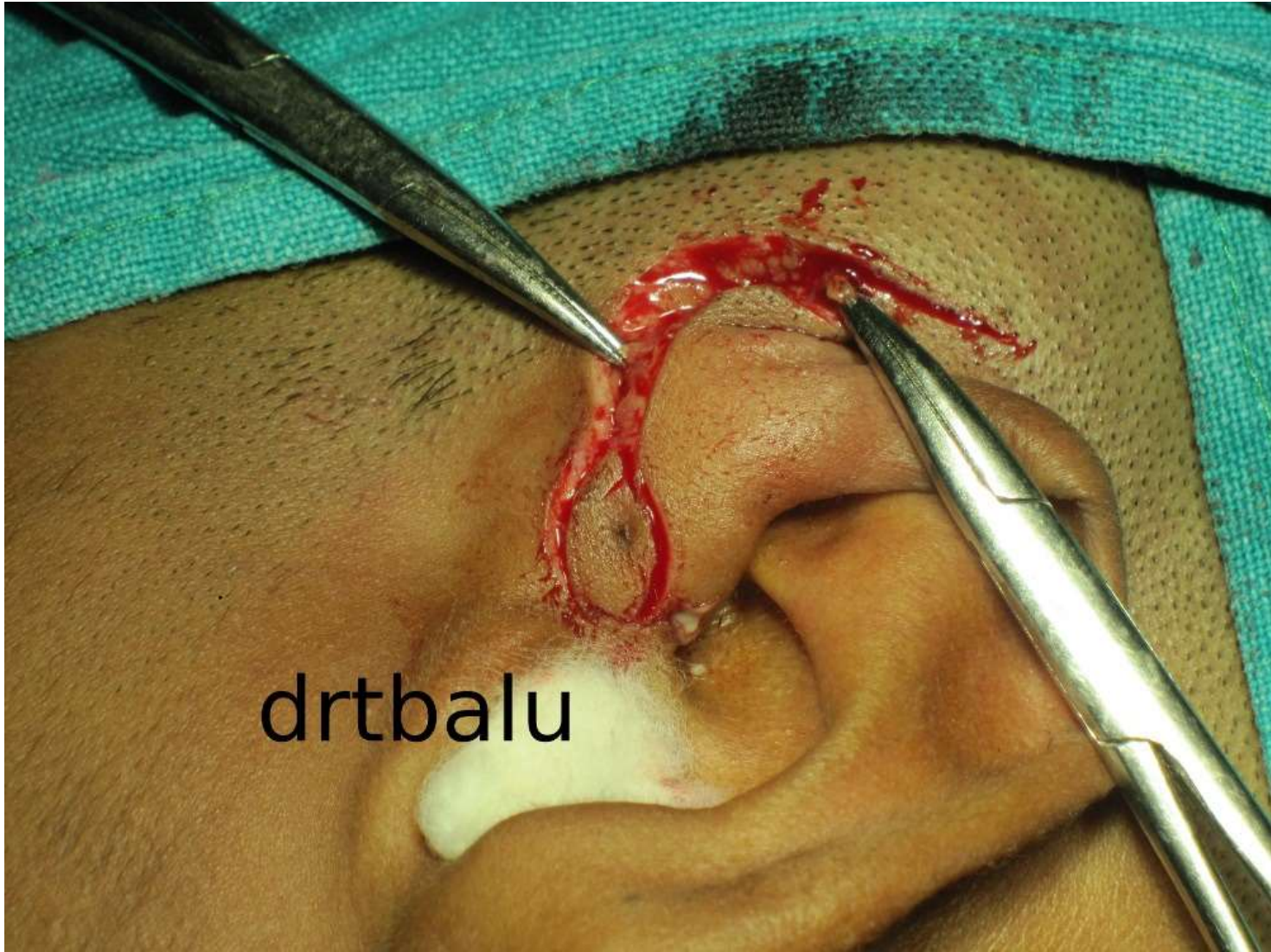
- Pinna Begins during the 6th week of gestation from 6 hillocks (Hillocks of His). 3 hillocks arise from caudal border of I arch? Other 3 arise from the cephalic border of II arch
  - Preauricular sinus theories
  - Incomplete fusion of Hillocks
  - Ectodermal infolding: Isolated ectodermal infolding?
  - Mode of inheritance? Autosomal dominant
  - Seen as a small pit along the anterior margin of ascending limb of helix. The tract usually blends with the perichondrium of auricle. Sinus tract is usually superior and lateral to facial nerve and parotid gland. Subcutaneous cyst formation in the area is common
  - Management is Complete removal with the tract





**Preauricular Sinus**



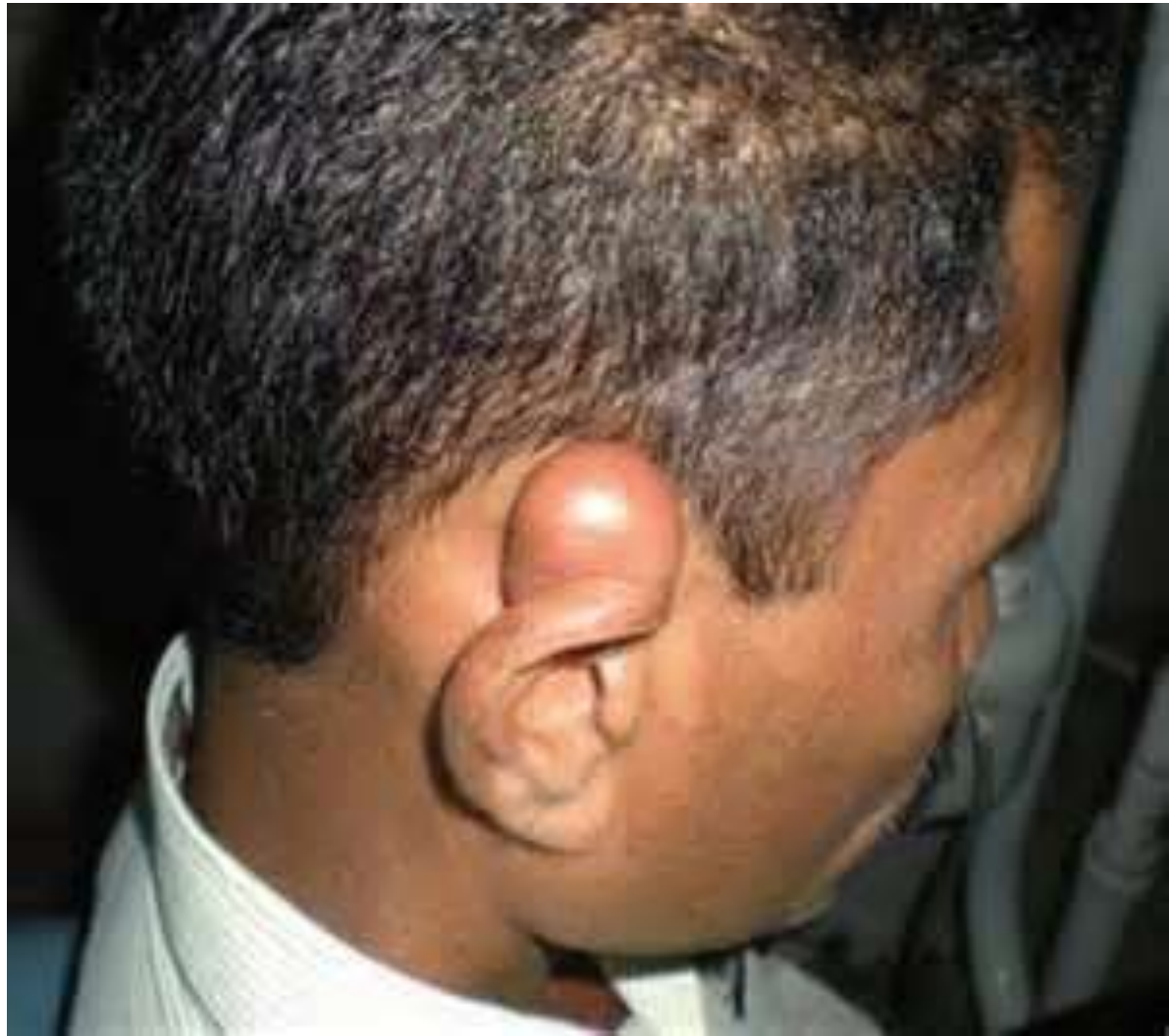

drtbalu



# Congenital swellings of pinna

- Dermoid
- Hemangiomas
- Lymphangiomas
- Collaural fistula
- This is an anomaly of first branchial cleft. One opening in the floor of external meatus and another one behind the angle of mandible close to the anterior border of sternomastoid muscle? Fistula passes through parotid gland close to facial nerve branches



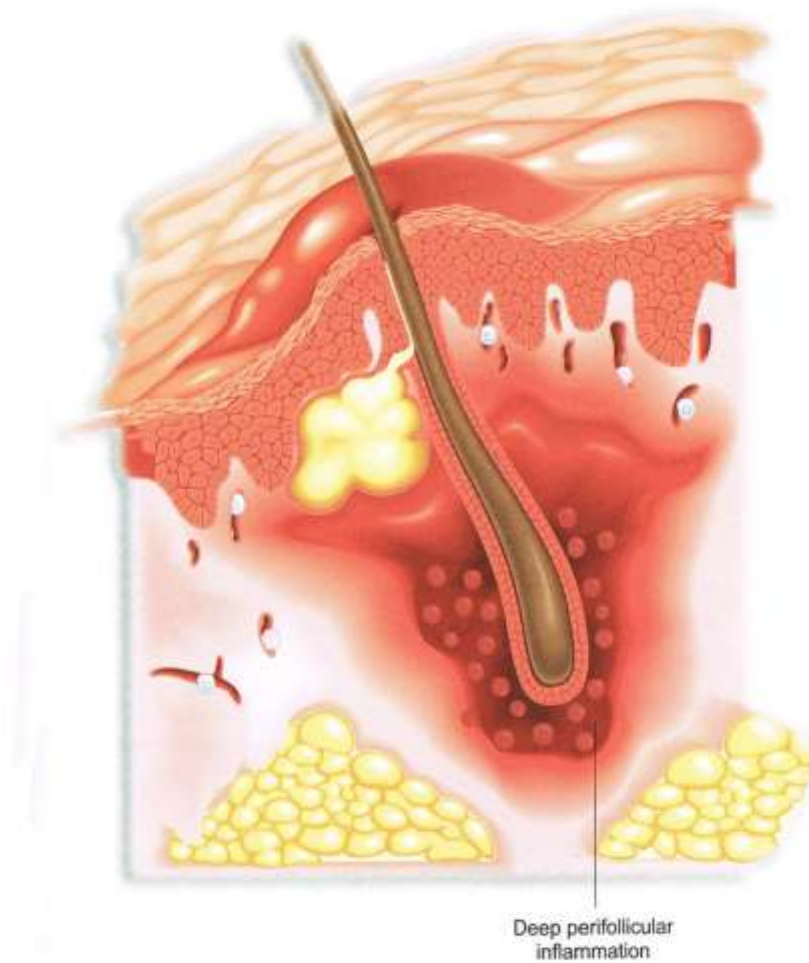
# Congenital anomalies of pinna

- Anotia
- Microtia
- Melotia
- Polyotia

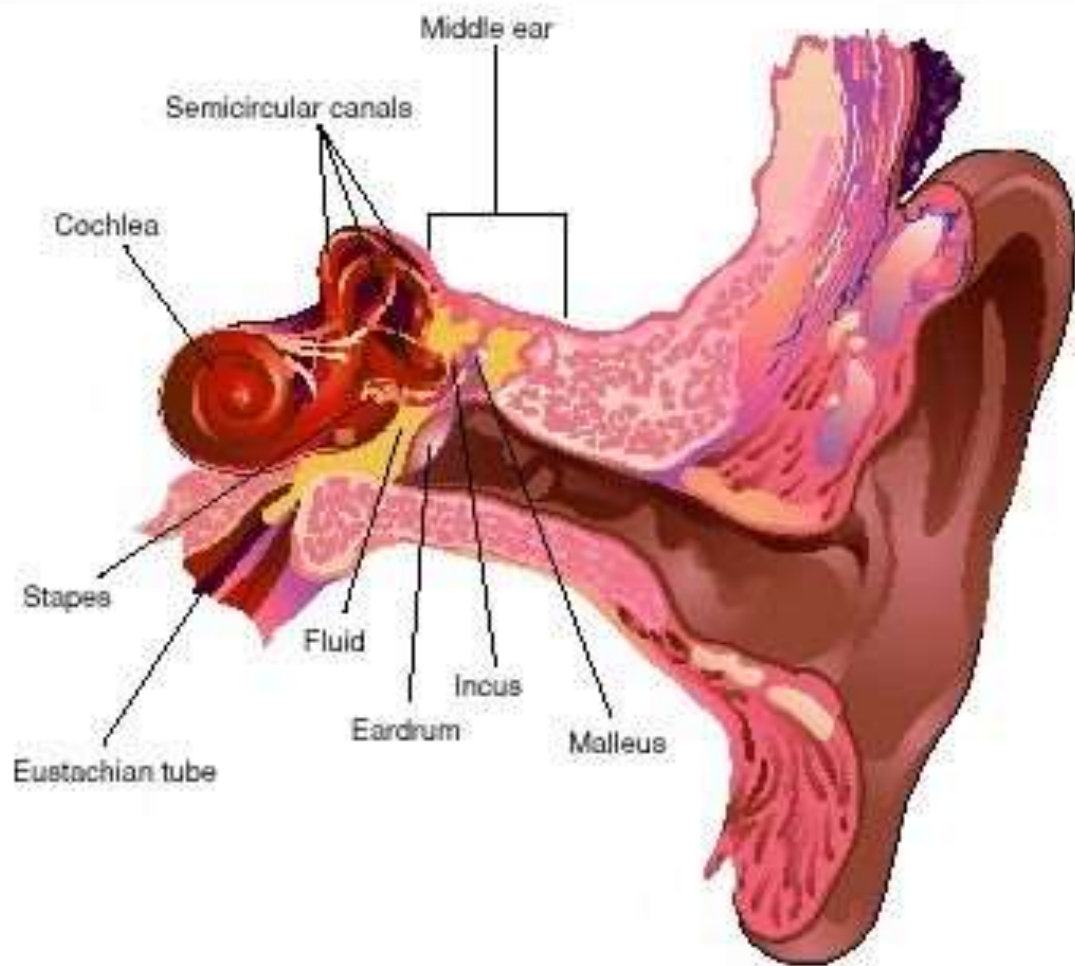
# Congenital atresia of external meatus

- Very rare congenital disorder. Caused by failure of canalization of first branchial cleft. Bony atretic plate may be present at the level of ear drum. Ossicular malformations common

# Furunculosis

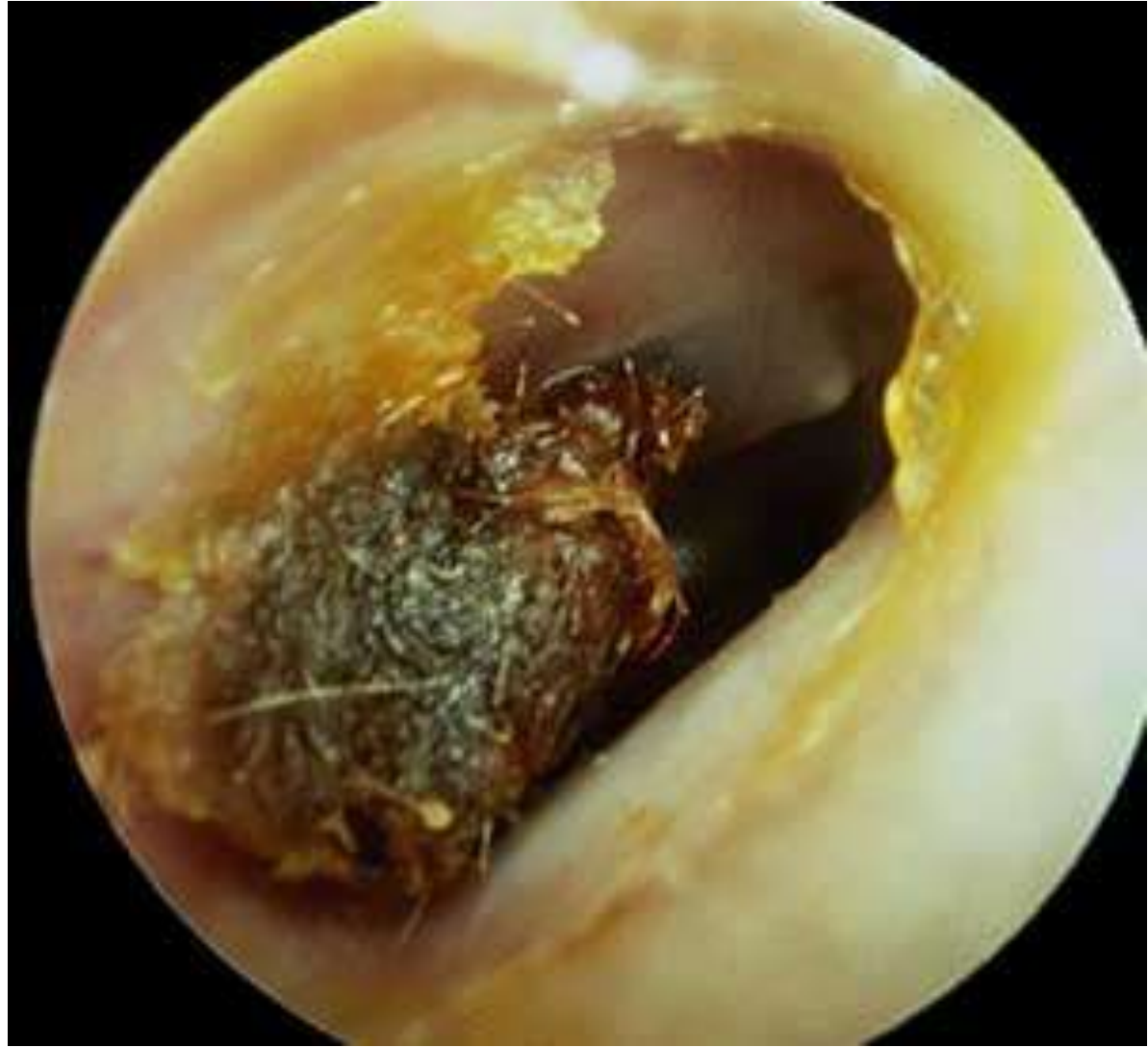

*By : Dr. Mohammad  
Suleiman*

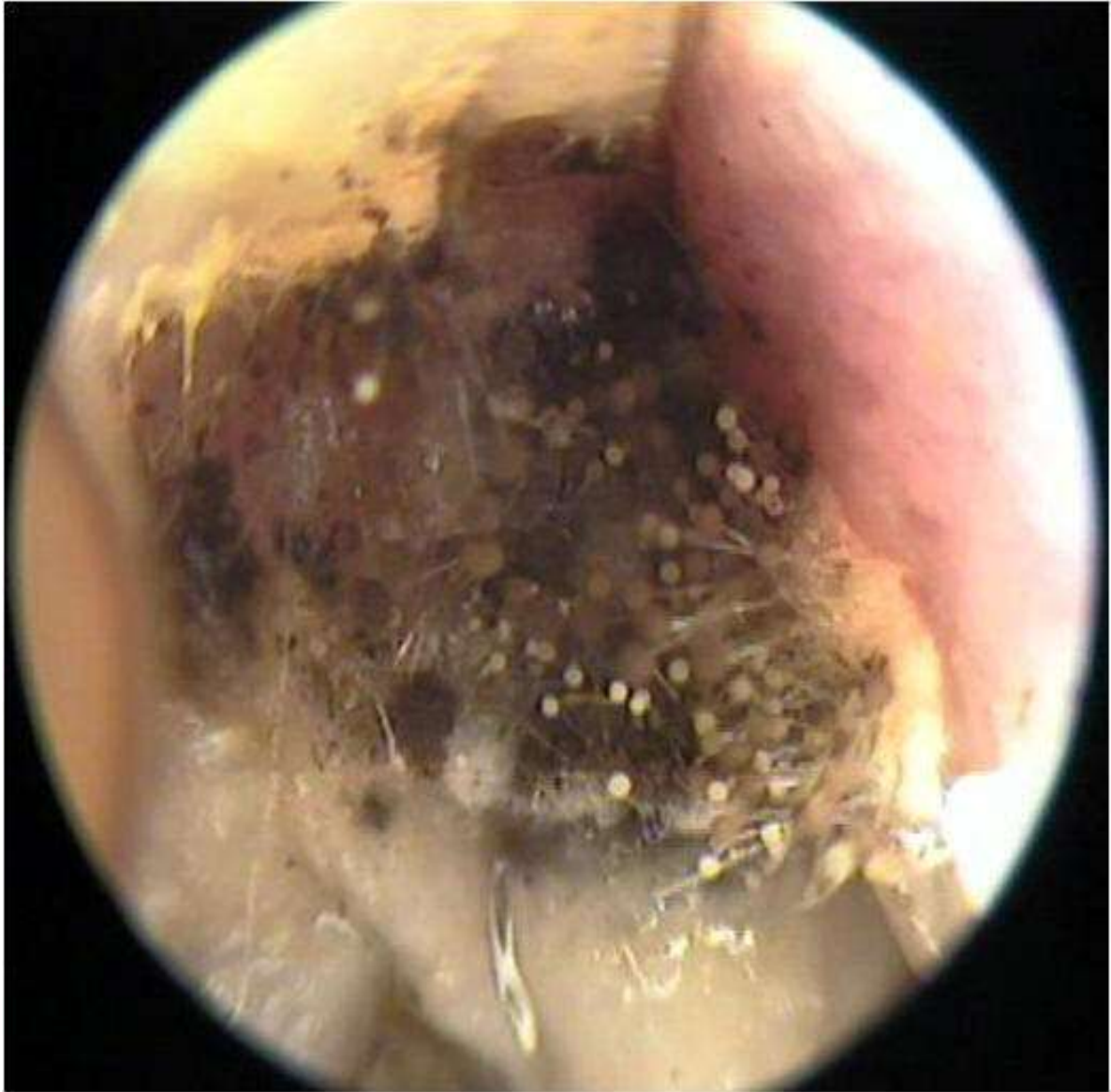

# OTITIS EXTERNA

- External otitis is infection of the ear canal & pinna
- External otitis is caused by bacteria or, rarely, fungi.
- Typical symptoms are itching, pain, and discharge.
- A doctor looks in the ear with an otoscope (a device for viewing the canal and eardrum) for redness, swelling, and pus.
- Debris removal, ear drops, and pain relievers are the most common forms of treatment.
- External otitis may affect the entire canal, as in generalized external otitis, or just one small area, as when pus accumulates in a boil (furuncle) or pimple.







# Causes

- A variety of bacteria or, rarely, fungi can cause generalized external otitis. Certain people, including those who have allergies, psoriasis, eczema, or scalp dermatitis, are particularly prone to external otitis. Injuring the ear canal while cleaning it or getting water or irritants, such as hair spray or hair dye, in the canal often leads to external otitis. External otitis is particularly common after swimming, in which case it is sometimes called swimmer's ear. Earplugs and hearing aids make external otitis more likely, particularly if these devices are not properly cleaned.

# Symptoms and Diagnosis

- Symptoms of generalized external otitis are itching and pain. Sometimes an unpleasant-smelling white or yellow discharge drains from the ear. The ear canal may have no swelling or slight swelling, or, in severe cases, it may be swollen completely closed. If the ear canal swells or fills with pus and debris, hearing is impaired. Usually, the canal is tender and hurts if the external ear (pinna) is pulled or if pressure is placed on the fold of skin in front of the ear canal (tragus). To a doctor looking into the ear canal through an otoscope, the skin of the canal appears red and swollen and may be littered with pus and debris.
- Boils cause severe pain. When they rupture, a small amount of blood and pus may leak from the ear.

# Prevention and Treatment

- Swimmer's ear may be prevented by putting drops of a solution containing half rubbing alcohol and half vinegar in the ear before and after swimming. Attempting to clean the canal with cotton swabs interrupts the normal, self-cleaning mechanism and can push debris toward the eardrum, where it accumulates. Also, these actions may cause minor damage that predisposes to external otitis.

- To treat generalized external otitis from any cause, a doctor first removes the infected debris from the canal with suction or dry cotton wipes. After the ear canal is cleared, hearing often returns to normal. Usually, a person is given ear drops containing vinegar and drops containing a corticosteroid such as hydrocortisone

- Analgesics such as acetaminophen
- or codeine may help reduce pain for the first 24 to 48 hours, until the inflammation begins to subside. An infection that has spread beyond the ear canal (cellulitis—see Bacterial Skin Infections: Cellulitis) may be treated with an antibiotic given by mouth.

- Treatment of boils depends on how advanced the infection is. In an early stage of infection, a heating pad can be applied for a short time and analgesics can be given to help relieve pain. The heat may also help speed healing. A boil that has come to a head is cut open to drain the pus. An antibiotic is then applied directly to the area or given by mouth.

# Malignant External Otitis

- Malignant external otitis is infection of the external ear that has spread to involve the skull bone containing part of the ear canal, the middle ear, and the inner ear (temporal bone).



- Malignant external otitis occurs mainly in people with weakened immune systems and in older people with diabetes. Infection of the external ear, usually caused by the bacteria *Pseudomonas*, spreads into the temporal bone, causing severe, life-threatening infection.
- People have severe earache, a foul-smelling discharge from the ear, and usually decreased hearing.
- The diagnosis is based on computed tomography (CT) scan results. Often doctors need to take a small piece of tissue from the ear canal to make sure that the symptoms are not the result of cancer.
- Malignant external otitis is treated with a 6-week course of antibiotics given by vein.

