

Deflected nasal septum

Anatomy

- Septal cartilage
- Vomer
- Perpendicular plate of ethmoid

Causes

- Birth trauma
- Accidental trauma
- Errors of development

Types of deformities

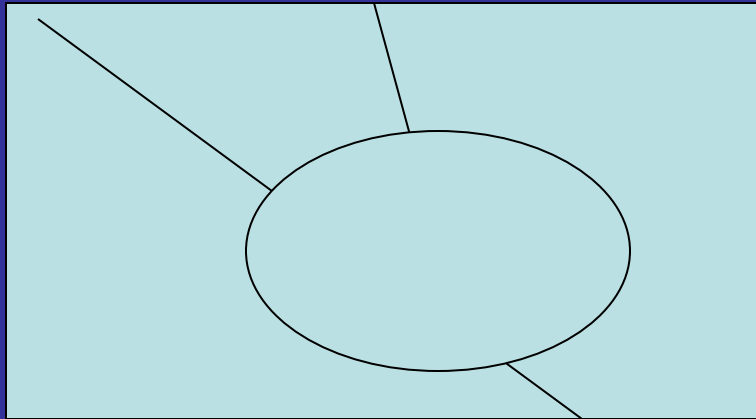
- Collumellar dislocation
- C-shape deviation
- S-shaped deviation
- Spurs

Clinical features

- Nasal obstruction
- External deformity
- Headache
- Epistaxis
- Rhinosinusitis

Treatment

- No treatment
- SMR
- Septoplasty
- Septorhinoplasty



Complications

- Infection
- Hemorrhage
- Septal hematoma
- Septal perforation
- Adhesions
- Saddling
- Flapping septum

Comparison of SMR & septoplasty

- Age
- Location of deformity
- Incision
- Technique
- Amount of cartilage removed
- Chances of complications

